



DATE PRESENTING CLINICAL SIGNS

5/4/22

Rapidly growing mass associated with P3 of 3rd digit of LH paw. Growing from area of nailbed. Ulcerated on surface. Radiograph reveals no pulmonary metastasis and no bony involvement of P3.

INTERPRETED BY CYTOLOGY SUBMISSION

L.D. McGill, DVM,
Ph.D, DACVP

FNA of Dermal Toe mass

PATIENT

Siena Viselli

OBSERVATIONS

Toe mass: Submitted are 5 excellent videos of moderate collections of cells from the toe mass on Siena. The cellularity is mixed with scattered neutrophils and moderate numbers of round cells. Some of the round cells have the appearance of lymphocytes and others have eccentric nuclei and there are binucleate cells present. There are scattered macrophages. Malignant cellularity is not confirmed in this collection.

INTERPRETATION OF THE FINDINGS & FURTHER RECOMMENDATIONS

SPECIES Total mass - Mixed cell collection with large numbers of round cells and possible round cell proliferative process.

Canine

COMMENTS

The cellularity is mixed and supports inflammation. Inflammation is certainly a part of the process.

BREED

Flat Coated Retriever

There are some characteristics of a few of the round cells that suggest the possibility of a plasmacytoma. There is inadequate cellularity to confirm that diagnosis but there are changes that are suspicious for that condition. Excision of the mass will be required to eliminate any process such as a plasmacytoma or possibly even a chronic inflammatory process. I was unable to identify adequate criteria of malignancy or evidence of sepsis and thus I suspect a low-grade proliferative process such as a plasmacytoma or a localized chronic inflammatory process. A repeat collection or biopsy will likely be required to confirm the process.

SEX

FS

AGE

8y

WEIGHT

71#

HOSPITAL NAME

Ruidoso Animal Clinic

REFERRING VET

Dr. Amanda Favis

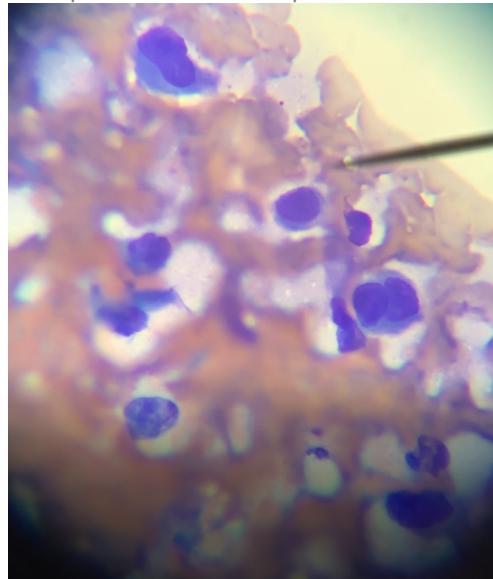


Image shows some of the round cells collected from Siena. There is a binucleated cell on the right. These are common in plasmacytomas.

INVOICE NUMBER

40512

The information and recommendations provided are based on the images presented by the referring veterinarian. No evaluation can be communicated regarding pathology that was not visible in the image/video clips provided.



DATE

5/4/22

Thank you for this referral. If the clinical or image interpretation does not parallel your findings or if I can be of any further assistance, please contact me.

INTERPRETED BY

L.D. McGill, DVM,
Ph.D, DACVP

L.D. McGill, DVM, Ph.D., DACVP

8288 Top of the World Drive
Cottonwood Heights, UT 84121
ldmcgill.vetpath@gmail.com
cell: 801-865-1220

PATIENT

Siena Viselli

SPECIES

Canine

BREED

Flat Coated Retriever

SEX

FS

AGE

8y

WEIGHT

71#

HOSPITAL NAME

Ruidoso Animal Clinic

REFERRING VET

Dr. Amanda Favis

INVOICE NUMBER

40512