



DATE PRESENTING CLINICAL SIGNS

5/4/22 Wide spleen on ultrasound.

CYTOLOGY SUBMISSION

FNA of Spleen

INTERPRETED BY

L.D. McGill, DVM,
Ph.D, DACVP

OBSERVATIONS

Spleen: Submitted are a large number of images and 2 videos of excellent collections of cells from the spleen in Molly. The cellularity is extremely uniform and consists entirely of cells with metachromatic to purple granules in their cytoplasm. These cells are almost all mast cells. There are very few other cells. They are irregularly granulated in this collection.

PATIENT

Molly Morrone

INTERPRETATION OF THE FINDINGS & FURTHER RECOMMENDATIONS

Spleen - Mast cell tumor of the spleen.

COMMENTS

SPECIES
Feline
This spleen is completely effaced with mast cells if this collection is representative. The mast cells are irregularly granulated. There is some suggestion that splenectomy in the cat may prolong life but mast cell neoplasia is expected to be terminal in the future. An unfavorable prognosis is warranted in my opinion. Other tissues easily could be involved in this process.

BREED

DSH

SEX

FS

AGE

13-year-old

WEIGHT

13 lbs

HOSPITAL NAME

Franklin Lakes Animal
Hospital

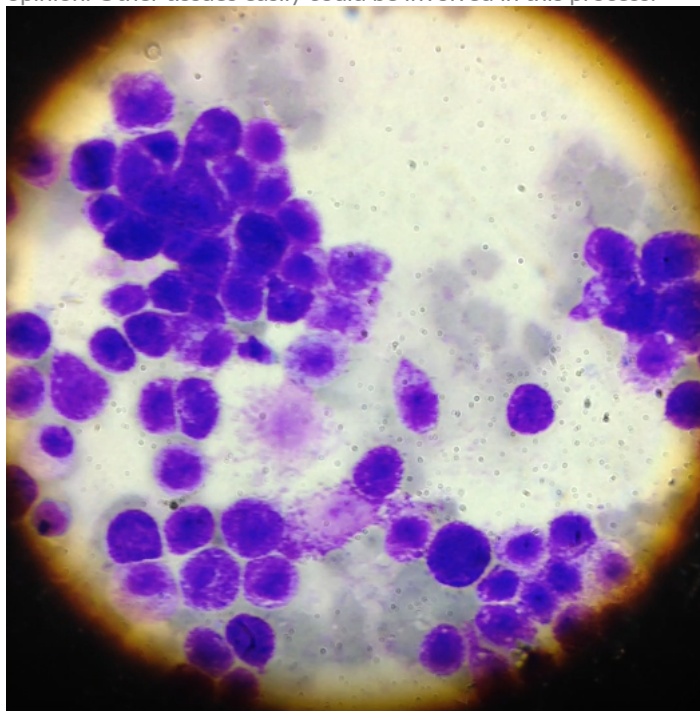


Image shows irregularly differentiated mast cells collected from the spleen in Molly. Over 98% of the cells are mast cells in this collection.

REFERRING VET

Dr. Alan Pomerantz

The information and recommendations provided are based on the images presented by the referring veterinarian. No evaluation can be communicated regarding pathology that was not visible in the image/video clips provided.

INVOICE NUMBER

40515

Thank you for this referral. If the clinical or image interpretation does not parallel your findings or if I can be of any further assistance, please contact me.



DATE

5/4/22 **L.D. McGill, DVM, Ph.D., DACVP**
8288 Top of the World Drive
Cottonwood Heights, UT 84121
ldmcgill.vetpath@gmail.com
cell: 801-865-1220

INTERPRETED BY

L.D. McGill, DVM,
Ph.D, DACVP

PATIENT

Molly Morrone

SPECIES

Feline

BREED

DSH

SEX

FS

AGE

13-year-old

WEIGHT

13 lbs

HOSPITAL NAME

Franklin Lakes Animal
Hospital

REFERRING VET

Dr. Alan Pomerantz

INVOICE NUMBER

40515