



DATE PRESENTING CLINICAL SIGNS

5/3/22

Seems painful, not eating well, hunched over. Chronic elevated liver enzymes. Had u/s at outside facility 12/21- heterogeneous liver. No current meds
ALT 907 (was 3085 1/25/22), bile acid pre >420 post 116.5, Neg Lepto

INTERPRETED BY CYTOLOGY SUBMISSION

L.D. McGill, DVM,
Ph.D, DACVP

Liver

OBSERVATIONS

Liver: Submitted are 4 excellent videos of excellent to moderate collections of hepatocytes from the liver in Pesto. The hepatocytes demonstrate slight granularity and minimal vacuolization. There are very few inflammatory cells associated with hepatocytes and in the surrounding red blood cells. There are no changes supporting malignant characteristics.

PATIENT

Pesto Sorrano

INTERPRETATION OF THE FINDINGS & FURTHER RECOMMENDATIONS

Liver - Mild hepatocellular vacuolization and granularity with minimal inflammation.

SPECIES

Canine

COMMENTS

The changes in the liver did not suggest any specific diagnosis. These changes are very likely secondary to other problems. The first condition that I would consider would be pancreatitis or enteritis. These changes in the liver can occur secondarily to those processes. There is no suggestion of malignancy or sepsis in this collection.

BREED

Maltese

SEX

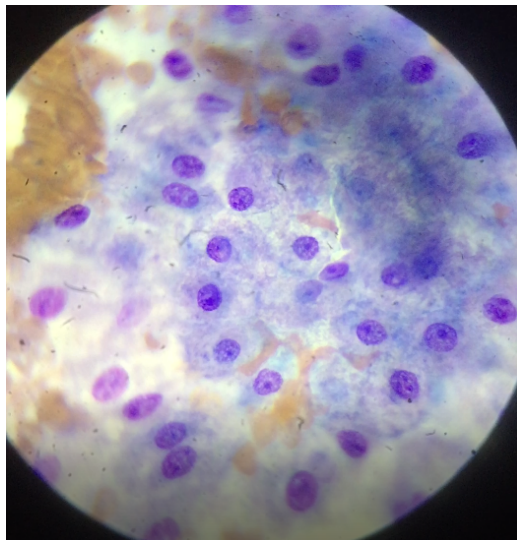
Male Neutered

AGE

3.5y

WEIGHT

12.75lbs



HOSPITAL NAME

Animal Care Centers
Flanders

Image shows a representative collection of hepatocytes from the liver in Pesto. The cells are relatively normal.

REFERRING VET

Dr. Hallihan

The information and recommendations provided are based on the images presented by the referring veterinarian. No evaluation can be communicated regarding pathology that was not visible in the image/video clips provided.

Thank you for this referral. If the clinical or image interpretation does not parallel your findings or if I can be of any further assistance please contact me.

INVOICE NUMBER

729



DATE

5/3/22

L.D. McGill, DVM, Ph.D., DACVP
8288 Top of the World Drive
Cottonwood Heights, UT 84121
ldmcgill.vetpath@gmail.com
cell: 801-865-1220

INTERPRETED BY

L.D. McGill, DVM,
Ph.D, DACVP

PATIENT

Pesto Sorrano

SPECIES

Canine

BREED

Maltese

SEX

Male Neutered

AGE

3.5y

WEIGHT

12.75lbs

HOSPITAL NAME

Animal Care Centers
Flanders

REFERRING VET

Dr. Hallihan

INVOICE NUMBER

729