

DATE PRESENTING CLINICAL SIGNS

5/28/22

Acute onset ataxia, lethargy, anemia. Ultrasound showed very enlarged spleen and liver with several prominent mesenteric lymph nodes.

INTERPRETED BY CYTOLOGY SUBMISSION

L.D. McGill, DVM,
Ph.D, DACVP

FNA of spleen performed with 25 g needle

PATIENT

Penny Calderon

OBSERVATIONS

Submitted are 5 excellent videos of moderate to excellent collections of cells from the spleen in Penny. The cellularity for the most part consists of round cells that are variable in size and shape. Many of these cells are small to intermediate lymphocytes but many are large and irregular. Even the small cells have nucleoli. Nucleoli and irregular nuclei are prominent. The cytoplasm is dark and granular. Mitotic figures are identified. There are scattered neutrophils and plasma cells in the collection.

SPECIES

Feline

INTERPRETATION OF THE FINDINGS & FURTHER RECOMMENDATIONS

Spleen - Massive numbers of lymphoid cells with increased atypical lymphoid cells suggesting lymphoma.

BREED

DSH

COMMENTS

The cellularity suggests the likelihood of early lymphoma. The cells appear to be intermediate to small cells throughout the collection. There are nucleated RBCs through the collection as well as some neutrophils but the major cellularity appears to be lymphoid cells. In some places I wondered about the possibility of early erythroleukemia but I cannot make that diagnosis. FeLV and FIV tests are encouraged if not already undertaken. Immunohistochemistry staining of this tissue will be required to make a diagnosis if chemotherapy is contemplated. An unfavorable prognosis is expected after evaluating this cytologic collection.

AGE

2 years

The information and recommendations provided are based on the images presented by the referring veterinarian. No evaluation can be communicated regarding pathology that was not visible in the image/video clips provided.

WEIGHT

12.5#

Thank you for this referral. If the clinical or image interpretation does not parallel your findings or if I can be of any further assistance please contact me.

HOSPITAL NAME

Rockaway Animal
Hospital

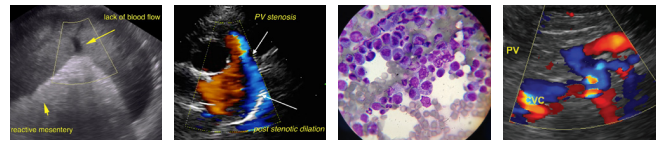
L.D. McGill, DVM, Ph.D., DACVP
8288 Top of the World Drive
Cottonwood Heights, UT 84121
ldmcgill.vetpath@gmail.com
cell: 801-865-1220

REFERRING VET

Dr. Maniar

INVOICE NUMBER

80297



DATE

5/28/22

INTERPRETED BY

L.D. McGill, DVM,
Ph.D, DACVP

PATIENT

Penny Calderon

SPECIES

Feline

BREED

DSH

SEX

FS

AGE

2 years

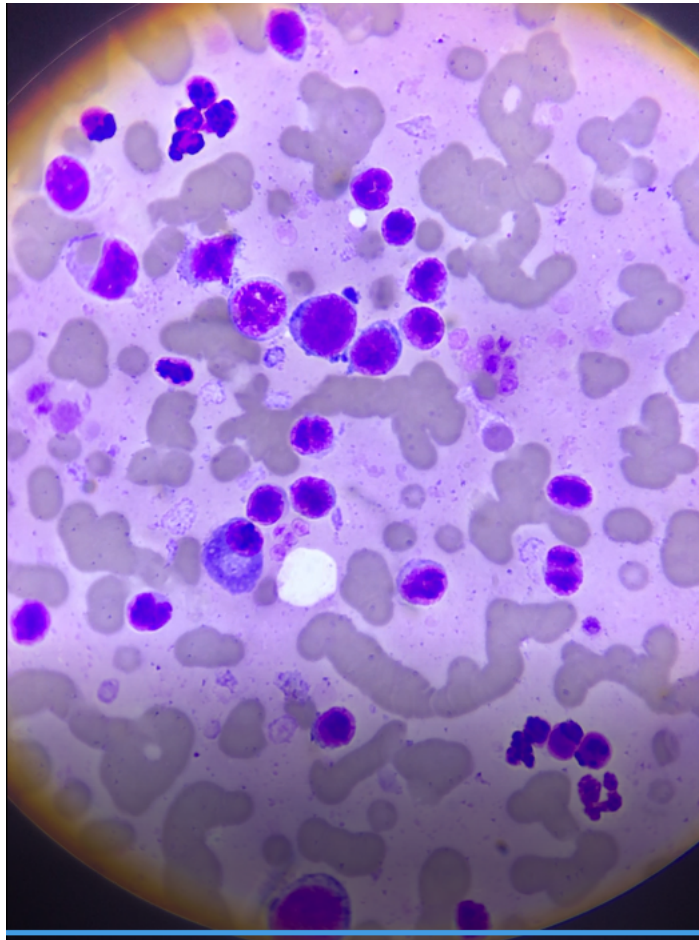


Image shows a field of round cells collected from the spleen in Penny. Note the large round cells and prominent nucleoli. A plasma cell and neutrophils are also present.

WEIGHT

12.5#

HOSPITAL NAME

Rockaway Animal
Hospital

REFERRING VET

Dr. Maniar

INVOICE NUMBER

80297