



DATE PRESENTING CLINICAL SIGNS

5/24/22

Not Patient presented for Annual Exam 5/24/2022. Noted a 1.8cm mass on lateral left abdomen. Very firm, subcutaneous, attached to abdomen wall. Has a 1 year history but has grown since noted 1 year ago.

INTERPRETED BY

L.D. McGill, DVM,
Ph.D, DACVP

CYTOLOGY SUBMISSION

FNA of Dermal

PATIENT

Faith Svingala

OBSERVATIONS

Dermal mass: Submitted are 2 excellent videos of minimal collections of cells on these smears collected from Faith. The cells are represented with round cells with granular material in their cytoplasm. Many of the granules are free. The smearing has separated the granules from the cells. Some of the cells have well granulated cytoplasm. The granules are metachromatic and characteristic of mast cell granules even when free around cells.

SPECIES

Canine

INTERPRETATION OF THE FINDINGS & FURTHER RECOMMENDATIONS

Dermal mass - Mast cell tumor

BREED

DobermanX

COMMENTS

The cells that are preserved are characteristic mast cells. Granules are prominent free in the surrounding fluid. This can occur in mast cell aspiration. The cells that are well granulated appear to be fairly mature. There are few cells that are minimally granulated but they do not appear to be aggressive. My suspicion is that this is a low-grade mast cell tumor, but excision is required. Excision by 2 cm is encouraged. A guarded prognosis is warranted with mast cell tumors.

SEX

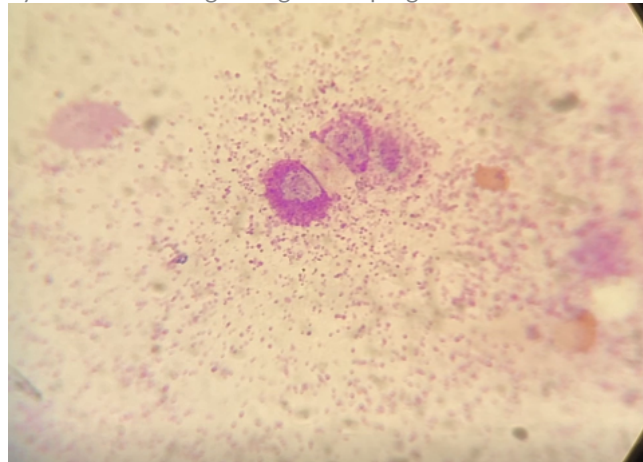
SF

AGE

9y

WEIGHT

61.6#



HOSPITAL NAME

Rotterdam Veterinary
Hospital

Image shows mast cells surrounded by free mast cell granules collected from Faith. There are also a couple of less well granulated mast cells in the image.

REFERRING VET

Dr. Amy Scarpinato

The information and recommendations provided are based on the images presented by the referring veterinarian. No evaluation can be communicated regarding pathology that was not visible in the image/video clips provided.

Thank you for this referral. If the clinical or image interpretation does not parallel your findings or if I can be of any further assistance, please contact me.

INVOICE NUMBER

40529



DATE

5/24/22 **L.D. McGill, DVM, Ph.D., DACVP**
8288 Top of the World Drive
Cottonwood Heights, UT 84121
ldmcgill.vetpath@gmail.com
cell: 801-865-1220

INTERPRETED BY

L.D. McGill, DVM,
Ph.D, DACVP

PATIENT

Faith Svingala

SPECIES

Canine

BREED

DobermanX

SEX

SF

AGE

9y

WEIGHT

61.6#

HOSPITAL NAME

Rotterdam Veterinary
Hospital

REFERRING VET

Dr. Amy Scarpinato

INVOICE NUMBER

40529