



DATE PRESENTING CLINICAL SIGNS

5/20/22

Patient has a history of severe dental disease, facial swelling, bloody nasal discharge. Patient presented 5/19/2022 for dental surgery. A slightly soft swelling was noted dorso-medial to OD. Skull radiographs were taken under sedation. The swelling was sampled via FNA. Dental surgery performed, diseased teeth removed.

INTERPRETED BY

L.D. McGill, DVM,
Ph.D, DACVP

CYTOLOGY SUBMISSION

FNA of Dermal

PATIENT

Fritz Mason

OBSERVATIONS

Swelling on head: Submitted are 3 excellent videos of moderate collections of cells from the swelling on the head of Fritz. The cellularity is smudged over the majority of the fields. Even the smudged cells suggest round cells but there are scattered plasma cells and neutrophils. Nuclear streaming as a result of smudged cells is prominent. Many of the cells appear to be naked nuclei as a result of smearing. The majority of the cells suggest round cells, but they cannot be interpreted since they are altered from the smearing process.

SPECIES

Canine

BREED

Miniature Daschund

INTERPRETATION OF THE FINDINGS & FURTHER RECOMMENDATIONS

Swelling on head - Suggestive of reactive lymph node with mild suppurative inflammation.

SEX

Male Neutered

COMMENTS

The cellularity is somewhat difficult to interpret but there is a suggestion that it is likely from lymphoid tissue. There appears to be inflammation draining to this location. The inflammation is neutrophilic with scattered plasma cells. I was unable to identify neoplastic cells in any of the fields. There still could be neoplasia present but due to the smearing, I was unable to identify that potential. Very likely this is a reactive lymph node to what is occurring secondarily to the dental response. If problems continue and further diagnostics are required, a repeat aspirate with the goal of careful smearing or follow-up biopsy of the region may be beneficial.

AGE

14y

WEIGHT

15.3#

HOSPITAL NAME

Rotterdam Veterinary
Hospital

REFERRING VET

Dr. Anna St Sir

INVOICE NUMBER

40525



DATE

5/20/22

INTERPRETED BY

L.D. McGill, DVM,
Ph.D, DACVP

PATIENT

Fritz Mason

SPECIES

Canine

BREED

Miniature Daschund

SEX

Male Neutered

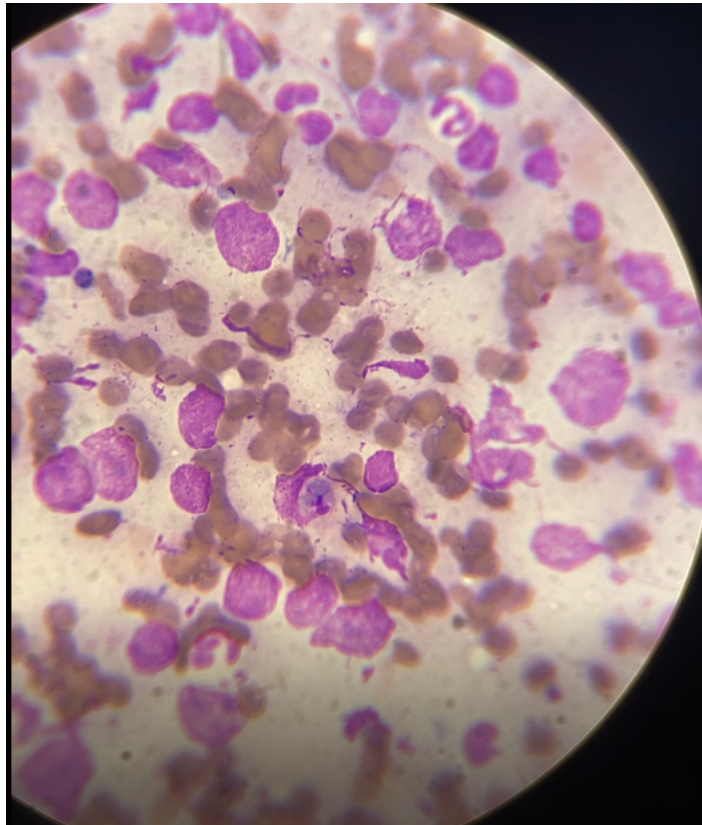


Image shows a representative field of cells collected from the head region on Fritz. Note the naked nuclei and a neutrophil in this field.

AGE

14y

The information and recommendations provided are based on the images presented by the referring veterinarian. No evaluation can be communicated regarding pathology that was not visible in the image/video clips provided.

WEIGHT

15.3#

Thank you for this referral. If the clinical or image interpretation does not parallel your findings or if I can be of any further assistance, please contact me.

HOSPITAL NAME

Rotterdam Veterinary
Hospital

L.D. McGill, DVM, Ph.D., DACVP
8288 Top of the World Drive
Cottonwood Heights, UT 84121
ldmcgill.vetpath@gmail.com
cell: 801-865-1220

REFERRING VET

Dr. Anna St Sir

INVOICE NUMBER

40525