



**DATE PRESENTING CLINICAL SIGNS**

5/2/23

Patient positive for FeLV, chronic URI. Presented 5/1 with fever of 106F, anorexia, lethargic, enlarged submandibular lymph nodes. Lymph nodes seem larger today. Samples taken via FNA from lymph node.

**INTERPRETED BY**

L.D. McGill, DVM,  
Ph.D, DACVP

**CYTOLOGY SUBMISSION**

FNA of Dermal

**PATIENT**

George V4V

**OBSERVATIONS**

Lymph node: Submitted are 2 good videos of good collections of cells from the lymph node in George. Most of the cells are round cells that are lymphoid cells with large lymphoid cells well represented. There are scattered neutrophils and rare macrophages. Small mature lymphocytes are scattered throughout. Smudge degenerate debris is prominent. There are scattered of RBCs in the collection. The large lymphoid cells demonstrate prominent irregular nucleoli to multiple nucleoli.

**SPECIES**

Feline

**BREED**

DSH

**INTERPRETATION OF THE FINDINGS & FURTHER RECOMMENDATIONS**

Lymph node - Suggestive of lymphoma with secondary inflammation.

**SEX**

MN

**COMMENTS**

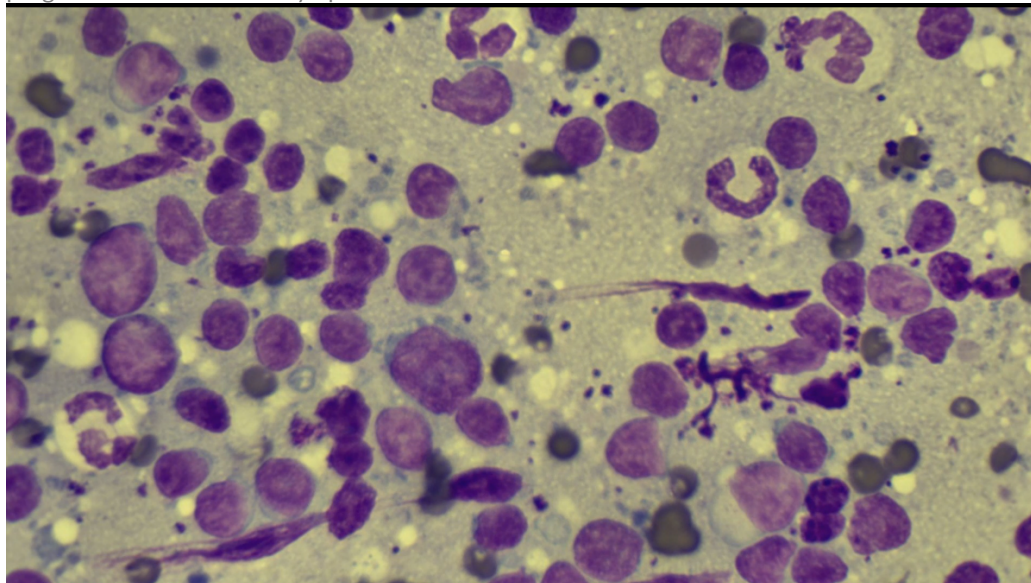
The cellularity is not effacing the lymph node in this instance but there are adequate numbers of large cells to cause suspicion for lymphoma. Further testing is required to confirm the diagnosis. This will likely require immunophenotyping. There is some inflammation in the collection. PARR testing on these slides may be beneficial or repeat collection may be required particularly if flow cytometry is considered. This cellularity is suggestive of lymphoma but not diagnostic. A guarded to unfavorable prognosis is warranted in my opinion.

**AGE**

4y

**WEIGHT**

11.8#



**HOSPITAL NAME**

Rotterdam Veterinary  
Hospital

**REFERRING VET**

Dr. Amy Scarpinato

**INVOICE NUMBER**

40715



**DATE** 5/2/23  
Image shows a group of lymphoid cells and a few neutrophils collected from George. The large lymphoid cells are of concern. Nucleoli are prominent in these cells.

**INTERPRETED BY** L.D. McGill, DVM, Ph.D., DACVP  
The information and recommendations provided are based on the images presented by the referring veterinarian. No evaluation can be communicated regarding pathology that was not visible in the image/video clips provided.

Thank you for this referral. If the clinical or image interpretation does not parallel your findings or if I can be of any further assistance, please contact me.

**PATIENT**  
George V4V  
**L.D. McGill, DVM, Ph.D., DACVP**  
8288 Top of the World Drive  
Cottonwood Heights, UT 84121  
ldmcgill.vetpath@gmail.com  
cell: 801-865-1220

**SPECIES**  
Feline

**BREED**  
DSH

**SEX**  
MN

**AGE**  
4y

**WEIGHT**  
11.8#

**HOSPITAL NAME**  
Rotterdam Veterinary  
Hospital

**REFERRING VET**  
Dr. Amy Scarpinato

**INVOICE NUMBER**  
40715