



DATE PRESENTING CLINICAL SIGNS

5/2/23

Blasto in the past, still pos. Treated for over a yr. Recurring pancreatitis

CYTOLOGY SUBMISSION

Pancreas

INTERPRETED BY

L.D. McGill, DVM,
Ph.D, DACVP

OBSERVATIONS

Pancreas: Submitted is a good video of moderate collections of cells from the pancreas and inflammation in Avery. Almost all of the nucleated cells that I could identify were neutrophils. Many of the cells are degenerate as you described. Necrosis is prominent. There is no suggestion of neoplasia or any other process. Bacterial organisms are prominent.

PATIENT

Avery Knauss

INTERPRETATION OF THE FINDINGS & FURTHER RECOMMENDATIONS

Pancreas - Suppurative inflammation with necrosis consistent with a pancreatic abscess and bacterial infection.

SPECIES COMMENTS

Canine

The cellularity is characteristic of an inflammatory process with necrosis. Even the smiley faces were neutrophils. There is degenerate debris and necrotic material throughout the collection. I saw structures that I expected were coccoid bacteria in several locations. There may have been others that I did not identify. There is no suggestion of malignancy but there is prominent inflammation and probable bacterial infection. Continued long-term therapy for pancreatitis and an abscess is in order. A guarded prognosis is warranted when this disease process becomes prolonged.

BREED

Gshp

SEX

Female Spayed

AGE

11

WEIGHT

60

HOSPITAL NAME

Bayshore Veterinary
Hospital

REFERRING VET

Dr. Hunt

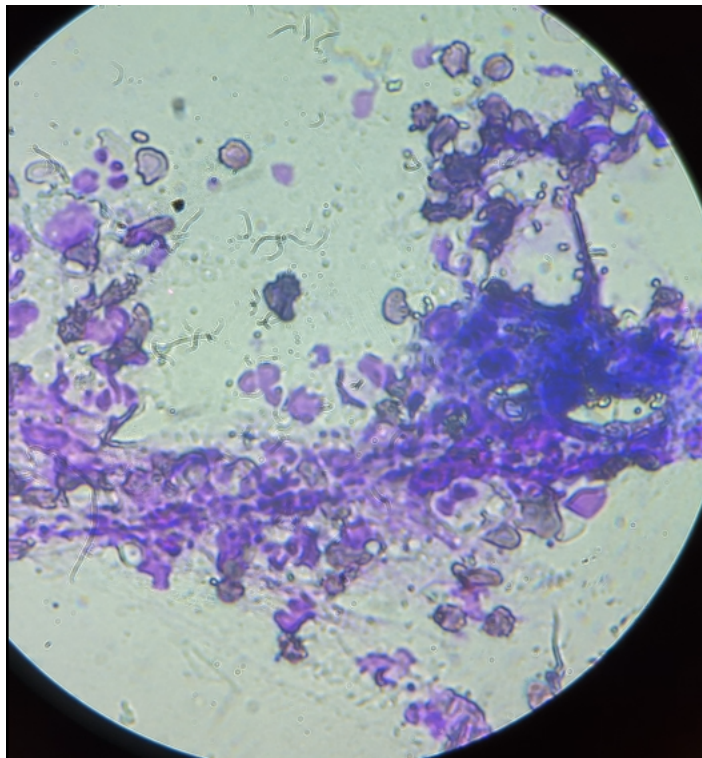


Image shows a group of cells most of which are degenerate neutrophils with necrosis collected from Avery. There are scattered intact neutrophils.

INVOICE NUMBER

942



DATE 5/2/23 The information and recommendations provided are based on the images presented by the referring veterinarian. No evaluation can be communicated regarding pathology that was not visible in the image/video clips provided.

INTERPRETED BY L.D. McGill, DVM, Ph.D., DACVP Thank you for this referral. If the clinical or image interpretation does not parallel your findings or if I can be of any further assistance please contact me.

L.D. McGill, DVM,
Ph.D., DACVP

L.D. McGill, DVM, Ph.D., DACVP
8288 Top of the World Drive
Cottonwood Heights, UT 84121
ldmcgill.vetpath@gmail.com
cell: 801-865-1220

PATIENT

Avery Knauss

SPECIES

Canine

BREED

Gshp

SEX

Female Spayed

AGE

11

WEIGHT

60

HOSPITAL NAME

Bayshore Veterinary
Hospital

REFERRING VET

Dr. Hunt

INVOICE NUMBER

942