



**DATE PRESENTING CLINICAL SIGNS**

5/14/22 FNA of liver mass.  
ALT 3130, AST 836. PLTs 271, HCT 44%. Coag: WNL.

**CYTOLOGY SUBMISSION**

**INTERPRETED BY** Liver

L.D. McGill, DVM,  
Ph.D, DACVP

**OBSERVATIONS**

Liver: Submitted are 8 excellent images and one excellent video of excellent collections of cells from the liver mass in Coby. There is excellent cellularity throughout these images and video. The cells are hepatocytes with prominent anisocytosis and anisokaryosis. Some of the cellularity is granular. The nuclei are extremely varied in size and shape. Some of the cells demonstrate open faced nuclei. There are cells that appear to be piling upon each other and are multi-nuclear. Very few inflammatory cells are identified.

**PATIENT**

Coby D'Elia

**INTERPRETATION OF THE FINDINGS & FURTHER RECOMMENDATIONS**

**SPECIES** Liver - Proliferative hepatocytes suggesting hepatocellular carcinoma.

Canine

**COMMENTS**

The cellularity in this collection suggests the likelihood of a proliferative process of hepatocytes. The nuclear characteristics are atypical enough to suggest carcinoma. It could be a rather proliferative hepatocellular adenoma. Exploratory and biopsy will be required to confirm the diagnosis. This should be confirmed before additional therapy is contemplated. A guarded to unfavorable prognosis is warranted after evaluating this cytologic collection.

**BREED**

Labradoodle

**SEX**

Male Neutered

**AGE**

7y

**WEIGHT**

Not provided

**HOSPITAL NAME**

Mt. Olive Veterinary  
Hospital

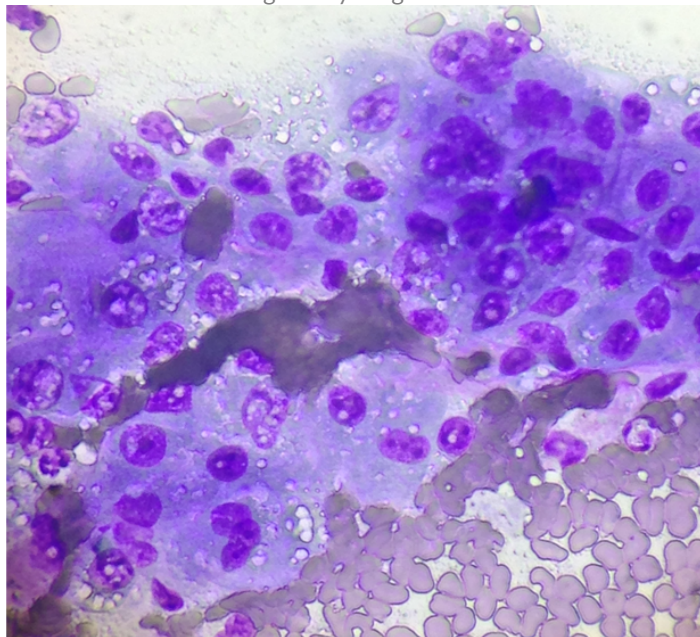


Image shows hepatocytes collected from the liver in Coby. Note the anisocytosis and anisokaryosis with a possible multinucleated cell in the lower location.

**REFERRING VET**

Dr. Logan

The information and recommendations provided are based on the images presented by the referring veterinarian. No evaluation can be communicated regarding pathology that was not visible in the image/video clips provided.

**INVOICE NUMBER**

733



**DATE** Thank you for this referral. If the clinical or image interpretation does not parallel your findings or if I can be of any further assistance please contact me.

5/14/22

**INTERPRETED BY** L.D. McGill, DVM, Ph.D., DACVP  
8288 Top of the World Drive  
Cottonwood Heights, UT 84121  
ldmcgill.vetpath@gmail.com  
cell: 801-865-1220

**PATIENT**

Coby D'Elia

**SPECIES**

Canine

**BREED**

Labradoodle

**SEX**

Male Neutered

**AGE**

7y

**WEIGHT**

Not provided

**HOSPITAL NAME**

Mt. Olive Veterinary  
Hospital

**REFERRING VET**

Dr. Logan

**INVOICE NUMBER**

733