



DATE PRESENTING CLINICAL SIGNS

5/12/22

Two day onset of mild lethargy, partial anorexia.
Labs done in January 2022 prior to TPLO surgery were normal including CBC< chems, T4, UA

INTERPRETED BY

L.D. McGill, DVM,
Ph.D, DACVP

CYTOLOGY SUBMISSION

Lymph node

OBSERVATIONS

Lymph node: Submitted are 5 excellent videos of excellent collections of cells from the lymph node in Roxie. The smears are excellent and interpretable. The nuclear characteristics of the round cells which are 98% of the cells on the smear are large and irregular. Nucleoli are variable and enlarged. Almost all of the cells are large atypical lymphoid cells. There are scattered neutrophils and rare macrophages in the collection. Mitotic figures are identified.

PATIENT

Roxie Flewellen

INTERPRETATION OF THE FINDINGS & FURTHER RECOMMENDATIONS

Lymph node - Consistent with high-grade lymphoma.

SPECIES

Canine

The cellularity in these excellent videos is most consistent with a high-grade lymphoma with large numbers of atypical lymphoid cells. Mitotic figures are easily identified. There are degenerate cells. There are a few small lymphocytes which accentuate the larger irregular atypical lymphoid cells. In my opinion, this is consistent with or even characteristic of a high-grade lymphoma. If chemotherapy is contemplated, then immunophenotyping of the cells to confirm the specific cell type may be beneficial for prognosis. The slides can be submitted for PCR testing or new slides that are not stained can be submitted for immunocytochemistry staining. Flow cytometry can be beneficial but will require a repeat collection of cells prior to submission to the laboratory. Contacting the laboratory to confirm how to submit flow cytometry samples is encouraged. Due to the atypical lymphoid cells, an unfavorable prognosis is warranted in my opinion. Roxie may respond to chemotherapy but continued monitoring is always in order.

BREED

Retriever mix

SEX

Female spayed

AGE

9.5y

WEIGHT

58lbs

HOSPITAL NAME

Friendship Springs
Veterinary Care

REFERRING VET

Dr. Cutchin

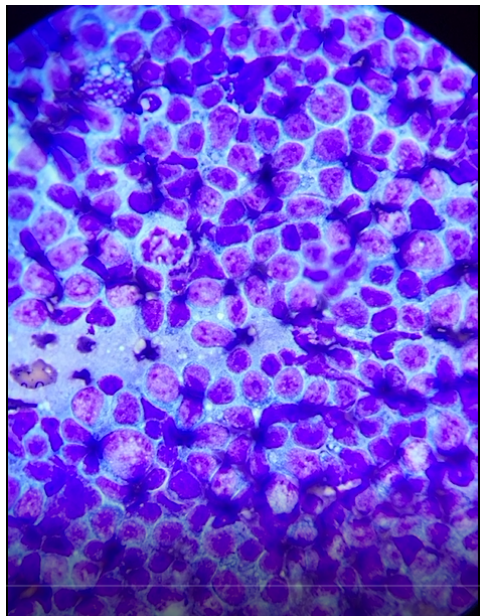


Image shows a representative collection of cells from the lymph node in Roxie. Note the very large cells and the mitotic figure in the upper left.

INVOICE NUMBER

731



DATE

5/12/22

The information and recommendations provided are based on the images presented by the referring veterinarian. No evaluation can be communicated regarding pathology that was not visible in the image/video clips provided.

INTERPRETED BY

L.D. McGill, DVM,
Ph.D, DACVP

Thank you for this referral. If the clinical or image interpretation does not parallel your findings or if I can be of any further assistance please contact me.

PATIENT

Roxie Flewellen

L.D. McGill, DVM, Ph.D., DACVP
8288 Top of the World Drive
Cottonwood Heights, UT 84121
ldmcgill.vetpath@gmail.com
cell: 801-865-1220

SPECIES

Canine

BREED

Retriever mix

SEX

Female spayed

AGE

9.5y

WEIGHT

58lbs

HOSPITAL NAME

Friendship Springs
Veterinary Care

REFERRING VET

Dr. Cutchin

INVOICE NUMBER

731