



**DATE PRESENTING CLINICAL SIGNS**

5/12/22

Patient has a history of ectopic stenotic ureters and pyelonephritis. Patient had surgical correction and ongoing treatment. Patient presented for Routine Exam 5/11/22 to update vaccines. Upon exam, prescapular lymph nodes are enlarged. Samples collected via fine needle aspirate.

**INTERPRETED BY CYTOLOGY SUBMISSION**

L.D. McGill, DVM,  
Ph.D, DACVP

FNA of Lymph node

**PATIENT**

Miska DillenBeck

**OBSERVATIONS**

Lymph node: Submitted are 2 excellent videos of moderate to excellent collections of cells from the lymph node in Miska. The cellularity demonstrates 80 to 90% of round cells that have minimal cytoplasm which is bluish gray. There are large cells present in the collection, but they are less than 50% of these round cells. The majority of the round cells are small mature lymphocytes with dark nuclei. There are scattered neutrophils and eosinophils. Scattered macrophages are identified. Atypical cells are not confirmed.

**SPECIES INTERPRETATION OF THE FINDINGS & FURTHER RECOMMENDATIONS**

Canine

Lymph node - Mild chronic suppurative lymphadenitis with reactive or stimulated lymph node tissue.

**COMMENTS**

**BREED**  
Bernese Mountain Dog

The cellularity in this collection is most characteristic of an inflammatory process. This inflammation could be a response to many different types of inflammation including tick borne infectious diseases. It could be draining inflammation from the oral cavity. The specific source for this reaction is not identified. Continued evaluation for other sources for inflammation is encouraged. Malignant characteristics are not identified in this collection but continued monitoring of Miska is warranted. An outside possibility is an early lymphoma. Sending the slides to the lab for PARR testing will rule out or in lymphoma.

**SEX**

F

**AGE**

11 M

**WEIGHT**

79.8#

**HOSPITAL NAME**

Rotterdam Veterinary  
Hospital

**REFERRING VET**

Dr. Anna St Sir

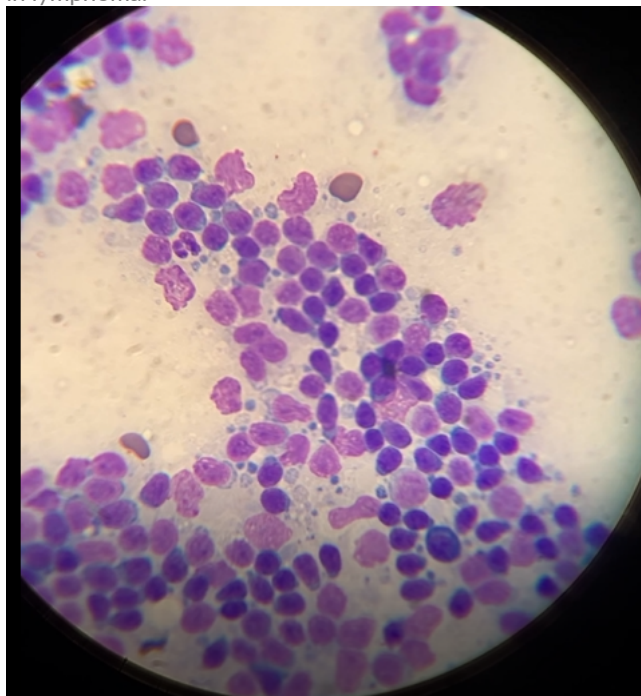


Image shows a field of representative cells from the lymph node in Miska. Note the small, dark mature lymphocytes, the neutrophil in the upper left and the plasma cell, lower right.

**INVOICE NUMBER**

40522



**DATE** 5/12/22 The information and recommendations provided are based on the images presented by the referring veterinarian. No evaluation can be communicated regarding pathology that was not visible in the image/video clips provided.

**INTERPRETED BY** L.D. McGill, DVM, Ph.D., DACVP Thank you for this referral. If the clinical or image interpretation does not parallel your findings or if I can be of any further assistance, please contact me.

L.D. McGill, DVM,  
Ph.D., DACVP

**L.D. McGill, DVM, Ph.D., DACVP**  
8288 Top of the World Drive  
Cottonwood Heights, UT 84121  
ldmcgill.vetpath@gmail.com  
cell: 801-865-1220

**PATIENT**

Miska DillenBeck

**SPECIES**

Canine

**BREED**

Bernese Mountain Dog

**SEX**

F

**AGE**

11 M

**WEIGHT**

79.8#

**HOSPITAL NAME**

Rotterdam Veterinary  
Hospital

**REFERRING VET**

Dr. Anna St Sir

**INVOICE NUMBER**

40522