



DATE PRESENTING CLINICAL SIGNS

5/12/22

PU/PD with normal appetite. Weight gain of 10 lbs. Urinary incontinence. No change after course of antibiotics (dilute urine, R/O UTI)
ALT 243, GGT 27, T Bili 0.8, Alb 4.4, Hct 60.4 Lepto PCR: NEG x 6 serovars.
AUS: Liver subjectively small, no overt masses. Adrenal glands WNL. Kidney and bladder WNL.

INTERPRETED BY

L.D. McGill, DVM,
Ph.D, DACVP

CYTOLOGY SUBMISSION

FNA of Liver

OBSERVATIONS

Liver: Submitted are 8 excellent videos of moderate to excellent collections of cells from the liver in Lily. The hepatocytes demonstrate vacuolization and granularity of the cytoplasm with one clump of small hepatocytes. The hepatocytes in some areas are moderately vacuolated. There is slight anisocytosis and anisokaryosis. The collection of mesothelial cells from the surface is observed. There are scattered inflammatory cells in the surrounding red blood cells which include neutrophils and lymphocytes. Malignant characteristics are not identified.

PATIENT

Lily Bartolini

SPECIES

Canine

INTERPRETATION OF THE FINDINGS & FURTHER RECOMMENDATIONS

Liver - Mild hepatocellular vacuolization and granularity with possible nodular hyperplasia.

COMMENTS

There are minimal changes in the liver collection from Lily. These changes suggest slight metabolic liver disease including the potential of secondary changes to pancreatitis or enteritis. There is no suggestion of neoplasia or of any primary liver disease in the collections available to evaluate. If problems continue, then further evaluation of internal organs is encouraged. Exploratory may be required to confirm the underlying process. Again, there is no suggestion of malignancy or sepsis.

BREED

Lab/Hound mix

SEX

FS

AGE

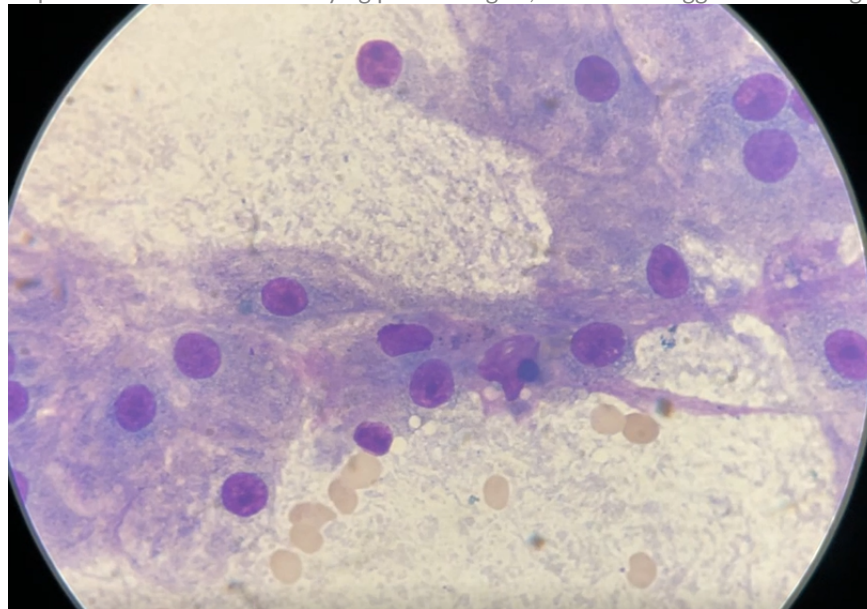
6 years

WEIGHT

78 lbs.

HOSPITAL NAME

Scanvet



REFERRING VET

Dr. Sheridan

The information and recommendations provided are based on the images presented by the referring veterinarian. No evaluation can be communicated regarding pathology that was not visible in the image/video clips provided.

INVOICE NUMBER

40521



DATE Thank you for this referral. If the clinical or image interpretation does not parallel your findings or if I can be of any further assistance, please contact me.

5/12/22

INTERPRETED BY L.D. McGill, DVM, Ph.D., DACVP
8288 Top of the World Drive
Cottonwood Heights, UT 84121
ldmcgill.vetpath@gmail.com
cell: 801-865-1220

PATIENT

Lily Bartolini

SPECIES

Canine

BREED

Lab/Hound mix

SEX

FS

AGE

6 years

WEIGHT

78 lbs.

HOSPITAL NAME

Scanvet

REFERRING VET

Dr. Sheridan

INVOICE NUMBER

40521