



DATE PRESENTING CLINICAL SIGNS

5/10/17

Previously submitted videos of spleen aspirate. 5/10/23

CYTOLOGY SUBMISSION

Liver

INTERPRETED BY

L.D. McGill, DVM,
Ph.D, DACVP

OBSERVATIONS

Liver: Submitted are 6 excellent videos of excellent collections of cells from the liver in Apple. The cellularity consists of good collections of hepatocytes in most of the videos. The hepatocytes demonstrate slightly granulated and vacuolated cytoplasm. The surrounding red blood cells contain a mixture of neutrophils, mature lymphocytes and rare macrophages. Neutrophils are associated with hepatocytes in several locations. Malignant characteristics are not identified in this collection.

PATIENT

Apple Nolan

INTERPRETATION OF THE FINDINGS & FURTHER RECOMMENDATIONS

Liver - Mild hepatocellular vacuolization and granularity with mild chronic suppurative hepatitis

SPECIES COMMENTS

Feline

The cellularity in this collection is supporting inflammation in the liver but there is no suggestion of lymphoma or neoplasia. The hepatocytes are likely responding secondarily to problems in other locations. This collection from the liver easily could be secondary to problems such as pancreatitis or enteritis. The problems in the spleen may be the result of lymphoma but not of involving the liver.

BREED

DSH

With the increased bilirubin, continued evaluation for the potential of pancreatitis is encouraged. I have seen several cases where bilirubin was the only elevated value in pancreatitis. A guarded prognosis is warranted in light of the results both from the spleen and the liver.

SEX

Female Spayed

AGE

10y

WEIGHT

7.9#

HOSPITAL NAME

Rotterdam Veterinary
Hospital

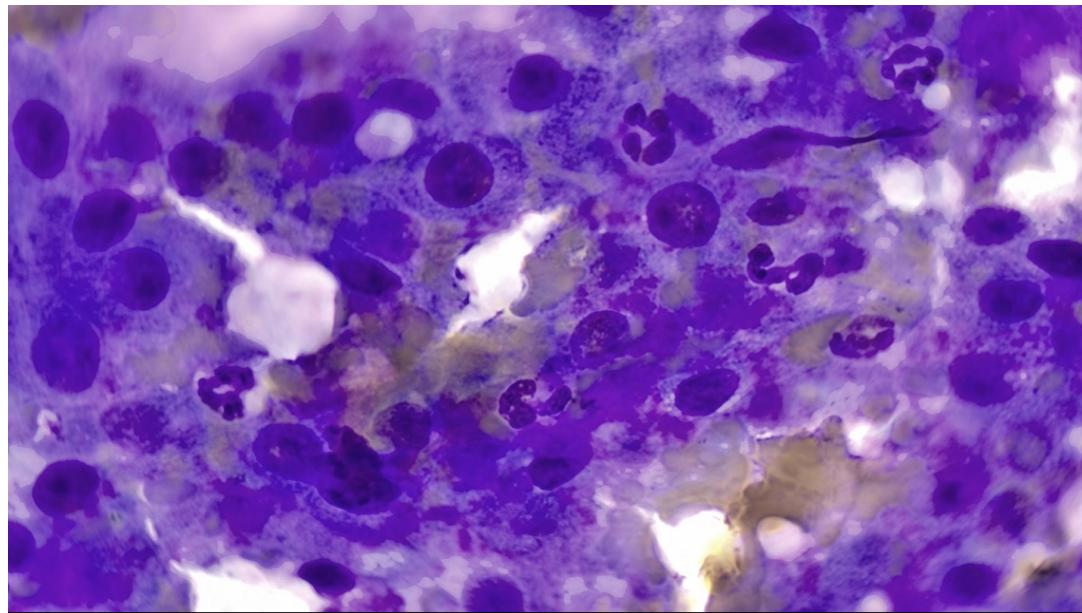


Image shows a group of hepatocytes and neutrophils collected from the liver in Apple. Lymphoid cells are not prominent in this collection.

REFERRING VET

Dr. St. Sir

The information and recommendations provided are based on the images presented by the referring veterinarian. No evaluation can be communicated regarding pathology that was not visible in the image/video clips provided.

INVOICE NUMBER

946



DATE

5/10/17

Thank you for this referral. If the clinical or image interpretation does not parallel your findings or if I can be of any further assistance please contact me.

INTERPRETED BY

L.D. McGill, DVM,
Ph.D, DACVP

L.D. McGill, DVM, Ph.D., DACVP
8288 Top of the World Drive
Cottonwood Heights, UT 84121
ldmcgill.vetpath@gmail.com
cell: 801-865-1220

PATIENT

Apple Nolan

SPECIES

Feline

BREED

DSH

SEX

Female Spayed

AGE

10y

WEIGHT

7.9#

HOSPITAL NAME

Rotterdam Veterinary
Hospital

REFERRING VET

Dr. St. Sir

INVOICE NUMBER

946