



**DATE PRESENTING CLINICAL SIGNS**

5/10/23

Patient presented 5/9 with history of decreased appetite, slightly lethargic. Patient dehydrated on exam, abdomen nonpainful. On ultrasound 5/10 spleen 1.2cm thick, coarse, irregular. Inflamed bile ducts. Coarse, hypoechoic liver. Elevated bilirubin

**INTERPRETED BY**

L.D. McGill, DVM,  
Ph.D, DACVP

**CYTOLOGY SUBMISSION**

FNA of Spleen

**PATIENT**

Apple Nolan

**OBSERVATIONS**

Spleen: Submitted are 6 excellent videos of excellent to very good collections of cells from the spleen in Apple. The cellularity consists of large numbers of round cells many of which have nuclei that are 4 to 8 times the size of red blood cells. The cells have irregular nucleoli. There are scattered plasma cells, neutrophils, and eosinophils. Macrophages with a vacuolated to granular cytoplasm are identified. There were a few small mature lymphocytes in the collection.

**SPECIES**

Feline

**BREED**

DSH

**INTERPRETATION OF THE FINDINGS & FURTHER RECOMMENDATIONS**

Spleen - Suggestive of lymphoma with mild inflammation.

**SEX**

SF

**COMMENTS**

The cellularity in many of the videos and many of the fields strongly suggest the likelihood of a lymphoma. It very easily could be a high-grade lymphoma. There is some inflammation which is interspersed throughout the collection. Further evaluation of the cells will be required to confirm the diagnosis if chemotherapy is contemplated. Immunophenotyping the slides may be beneficial. With the elevated bilirubin, I suspect that the liver is also involved. Aspiration of that organ may be beneficial in confirming the diagnosis. A guarded to unfavorable prognosis is warranted in Apple with the cells identified on this aspiration.

**AGE**

10y

**WEIGHT**

7.9#

**HOSPITAL NAME**

Rotterdam Veterinary  
Hospital

**REFERRING VET**

Dr. Anna St.Sir

**INVOICE NUMBER**

40726



**DATE**

5/10/23

**INTERPRETED BY**

L.D. McGill, DVM,  
Ph.D, DACVP

**PATIENT**

Apple Nolan

**SPECIES**

Feline

**BREED**

DSH

**SEX**

SF

**AGE**

10y

**WEIGHT**

7.9#

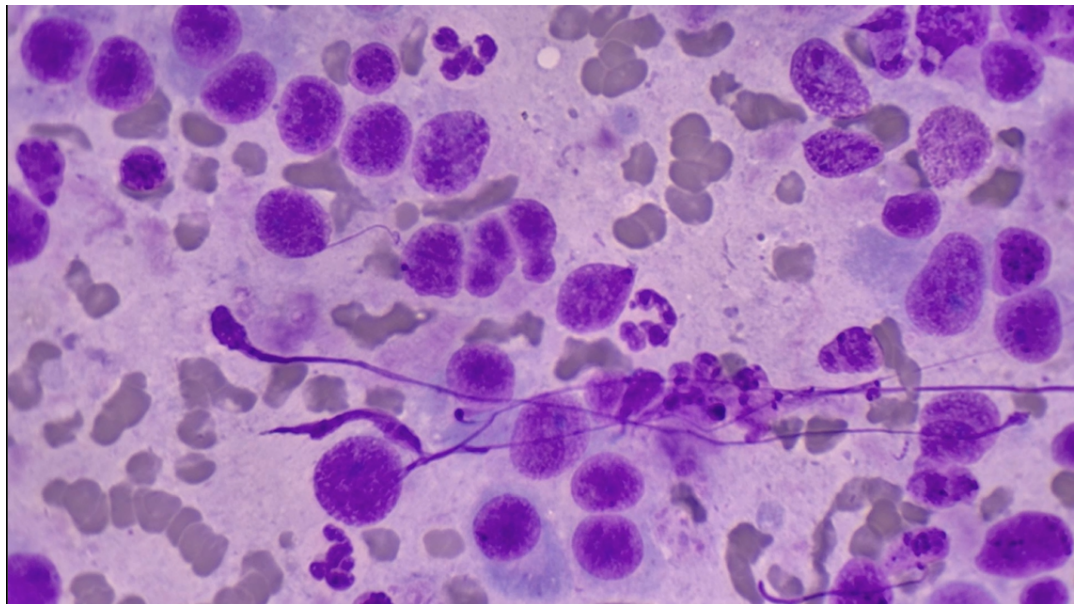


Image shows a large field of large irregular cells collected from the spleen in Apple. There are scattered neutrophils and 1 or 2 small lymphocytes. The rest for large irregular round cells.

The information and recommendations provided are based on the images presented by the referring veterinarian. No evaluation can be communicated regarding pathology that was not visible in the image/video clips provided.

Thank you for this referral. If the clinical or image interpretation does not parallel your findings or if I can be of any further assistance, please contact me.

**L.D. McGill, DVM, Ph.D., DACVP**  
8288 Top of the World Drive  
Cottonwood Heights, UT 84121  
ldmcgill.vetpath@gmail.com  
cell: 801-865-1220

**HOSPITAL NAME**

Rotterdam Veterinary  
Hospital

**REFERRING VET**

Dr. Anna St.Sir

**INVOICE NUMBER**

40726