



DATE PRESENTING CLINICAL SIGNS

4/9/22

Previously healthy cat hospitalized with azotemia past 2 days, labs improving with diuresis and GI support. Ultrasound last night showed large nodular kidneys with subcapsular rim of fluid. Aspirates taken of kidneys

INTERPRETED BY CYTOLOGY SUBMISSION

Kidney aspirate

L.D. McGill, DVM,
Ph.D, DACVP

OBSERVATIONS

Kidney: Submitted are 3 excellent videos of cells collected from the kidney in Pancake. The majority of the cells are round cells with minimal cytoplasm. Some of the cells are naked nuclei. The cytoplasm where noted is narrow and is bluish gray. The nuclei are large. In some areas they are variable. Nucleoli are prominent. These cells are almost all lymphoid cells and they appear to be neoplastic.

PATIENT

Pancake Estep

INTERPRETATION OF THE FINDINGS & FURTHER RECOMMENDATIONS

Kidney aspirate - High-grade lymphoma.

SPECIES

Feline

COMMENTS

The cellularity in this collection is essentially diagnostic for high-grade lymphoma. When the kidneys are infiltrated as much as these must be, then an unfavorable prognosis is warranted. There is some degeneration of the cells. Other areas in Pancake may be involved. Immunophenotyping these cells can be undertaken but in my understanding, this is not as prognostic in the cat as in the dog. Again, in my opinion, an unfavorable prognosis is warranted.

BREED

DLH

SEX

Male Neutered

AGE

5y

WEIGHT

7.5kg

HOSPITAL NAME

Animal Emergency Care

REFERRING VET

Dr. Drummond

INVOICE NUMBER

713

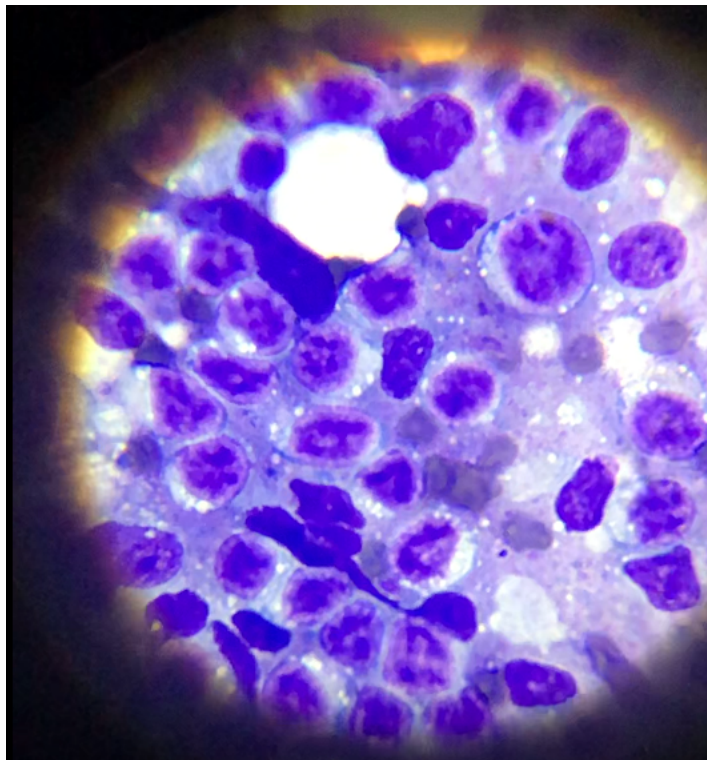


Image shows a field of lymphoid cells collected from Pancake. Note the very large cells and prominent nucleoli.



DATE

4/9/22

The information and recommendations provided are based on the images presented by the referring veterinarian. No evaluation can be communicated regarding pathology that was not visible in the image/video clips provided.

INTERPRETED BY

L.D. McGill, DVM,
Ph.D, DACVP

Thank you for this referral. If the clinical or image interpretation does not parallel your findings or if I can be of any further assistance please contact me.

PATIENT

Pancake Estep

L.D. McGill, DVM, Ph.D., DACVP
8288 Top of the World Drive
Cottonwood Heights, UT 84121
ldmcgill.vetpath@gmail.com
cell: 801-865-1220

SPECIES

Feline

BREED

DLH

SEX

Male Neutered

AGE

5y

WEIGHT

7.5kg

HOSPITAL NAME

Animal Emergency Care

REFERRING VET

Dr. Drummond

INVOICE NUMBER

713