



DATE PRESENTING CLINICAL SIGNS

4/9/22

Patient presented on 4/8/2022 for Annual Exam. A cutaneous mass of 5.3cmX4.8cm was found on the chest/ventral cervical/point of sternum. A smaller area of firm material can be felt deep inside the mass. The mass has an unknown duration.

INTERPRETED BY CYTOLOGY SUBMISSION

L.D. McGill, DVM,
Ph.D, DACVP

Skin mass

OBSERVATIONS

Skin mass: Submitted are 2 excellent videos of excellent collections of cells from the skin mass in Bullwinkle. The cells are rather uniform round cells with prominent metachromatic to purple granules in their cytoplasm. There is some hemorrhage and protein in the background. Minimal other inflammatory cells are identified. The proliferative cells are characteristic well granulated mast cells.

PATIENT

Bullwinkle Mallia

INTERPRETATION OF THE FINDINGS & FURTHER RECOMMENDATIONS

Skin mass - Mast cell tumor

SPECIES

Canine

COMMENTS

The granularity in these mast cells supports characteristic mast cell tumor with some suggestion of low-grade mast cell neoplasia. This is due to the uniform size of the cells and the rather consistent granularity. Excision of the mass is encouraged. A 2 centimeter clear area around these growths is suggested. A guarded prognosis is suggested with mast cell neoplasia due to the unpredictable nature of some of these growths. If additional staging is required, aspiration of the liver and spleen is a good practice.

BREED

LabX

SEX

Male Neutered

AGE

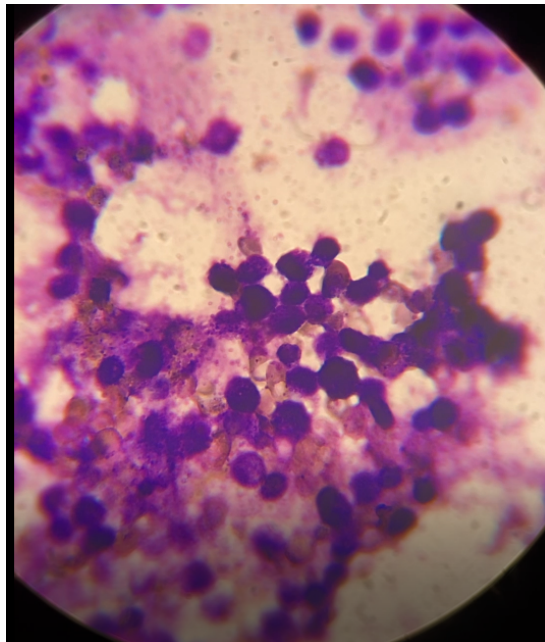
14y

WEIGHT

50.4

HOSPITAL NAME

Rotterdam Veterinary
Hospital



REFERRING VET

Dr. Scarpinato

Image shows well granulated mast cells collected from Bullwinkle. The cellularity in these videos suggests a low-grade mast cell tumor.

INVOICE NUMBER

712



DATE

4/9/22

The information and recommendations provided are based on the images presented by the referring veterinarian. No evaluation can be communicated regarding pathology that was not visible in the image/video clips provided.

INTERPRETED BY

L.D. McGill, DVM,
Ph.D., DACVP

Thank you for this referral. If the clinical or image interpretation does not parallel your findings or if I can be of any further assistance please contact me.

PATIENT

Bullwinkle Mallia

L.D. McGill, DVM, Ph.D., DACVP
8288 Top of the World Drive
Cottonwood Heights, UT 84121
ldmcgill.vetpath@gmail.com
cell: 801-865-1220

SPECIES

Canine

BREED

LabX

SEX

Male Neutered

AGE

14y

WEIGHT

50.4

HOSPITAL NAME

Rotterdam Veterinary
Hospital

REFERRING VET

Dr. Scarpinato

INVOICE NUMBER

712