



DATE PRESENTING CLINICAL SIGNS

4/7/22

History of cutaneous MCT and elevated LE. Under the care of an oncologist. On Denamarin and Dasequin. Treated with a short course of Prednisone in January for an ear infection. AUS today to evaluate elevated LE. USG Liver FNA done.

INTERPRETED BY CYTOLOGY SUBMISSION

Liver

L.D. McGill, DVM,
Ph.D, DACVP

OBSERVATIONS

Liver: Submitted are 6 excellent videos of moderate collections of hepatocytes from the liver in Maggie. The hepatocytes demonstrate vacuolization in irregular packets. Other hepatocytes demonstrate relatively normal cytoplasm. The nuclear patterns in the hepatocytes are within normal limits. Scattered neutrophils are observed. There are no suggestions of neoplasia or sepsis.

PATIENT

Maggie Gray

INTERPRETATION OF THE FINDINGS & FURTHER RECOMMENDATIONS

Liver - Multifocal hepatocellular lipidosis consistent with metabolic liver changes.

SPECIES

Canine

COMMENTS

The changes in this collection support multifocal lipidosis and vacuolization. This is commonly identified with steroid hepatopathy. In some dogs, treatment with steroids one time can be enough to cause hepatocellular abnormalities. There is no suggestion of malignancy or sepsis. Continued monitoring of the liver is encouraged however no primary liver disease can be suggested at this time.

BREED

Beagle

SEX

Female Spayed

AGE

12y

WEIGHT

30 lbs

HOSPITAL NAME

Scanvet

REFERRING VET

Dr. Lipovsky

INVOICE NUMBER

710

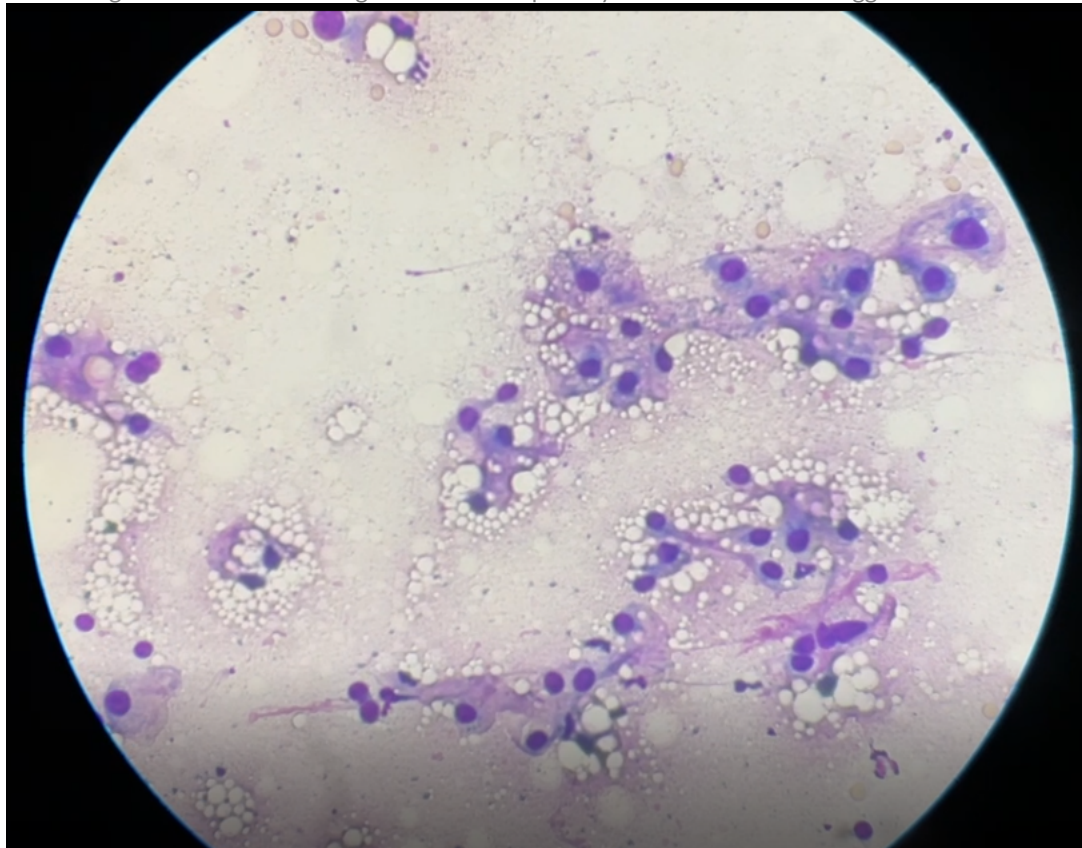


Image shows hepatocytes associated with lipid in and possibly outside the cells. It is fat as you noted and really the only lesion observed.



DATE

4/7/22

The information and recommendations provided are based on the images presented by the referring veterinarian. No evaluation can be communicated regarding pathology that was not visible in the image/video clips provided.

INTERPRETED BY

L.D. McGill, DVM,
Ph.D, DACVP

Thank you for this referral. If the clinical or image interpretation does not parallel your findings or if I can be of any further assistance please contact me.

PATIENT

Maggie Gray

L.D. McGill, DVM, Ph.D., DACVP
8288 Top of the World Drive
Cottonwood Heights, UT 84121
ldmcgill.vetpath@gmail.com
cell: 801-865-1220

SPECIES

Canine

BREED

Beagle

SEX

Female Spayed

AGE

12y

WEIGHT

30 lbs

HOSPITAL NAME

Scanvet

REFERRING VET

Dr. Lipovsky

INVOICE NUMBER

710