



DATE PRESENTING CLINICAL SIGNS

4/7/22

Patient presented for grooming 4/7/22. After shaving, a 2.1cm mass was found on the right rump near the base of the tail. No prior history of the mass has been noted.

CYTOLOGY SUBMISSION

INTERPRETED BY

Skin lesion

L.D. McGill, DVM,
Ph.D, DACVP

OBSERVATIONS

Skin lesion near the base of the tail: Submitted are 4 excellent videos of minimal to moderate cellular collection. The cellular collection is mixed. There are scattered macrophages interspersed with neutrophils, eosinophils and some small mature lymphocytes. Scattered spindloid cells are present. There is hemorrhage and protein. Scattered keratinized cells are identified. Malignant characteristics are not identified.

PATIENT

Cleo Kelly

INTERPRETATION OF THE FINDINGS & FURTHER RECOMMENDATIONS

Skin lesion - Chronic pyogranulomatous inflammation with fibrosis.

SPECIES

Feline

COMMENTS

The cellularity in this collection is most characteristic of a chronic inflammatory process. This could be the result of a bite lesion or could be the result of localized inflammation even as a result of a ruptured keratinized structure. There is no suggestion of malignancy or sepsis. Treatment for inflammation in this region is encouraged. A favorable prognosis is expected. There is an outside possibility of this being a localized area of inflammation within a neoplastic process but the cellularity was all inflammatory.

BREED

DLH

SEX

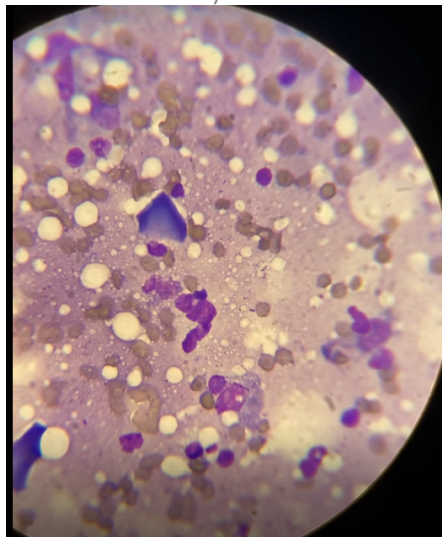
Male Neutered

AGE

5y

WEIGHT

14.4



HOSPITAL NAME

Rotterdam Veterinary
Hospital

Image shows mixed cells with macrophages, lymphocytes and polymorphonuclear cells collected from Cleo. Keratinized cells are present.

REFERRING VET

Dr. Scarpinato

The information and recommendations provided are based on the images presented by the referring veterinarian. No evaluation can be communicated regarding pathology that was not visible in the image/video clips provided.

Thank you for this referral. If the clinical or image interpretation does not parallel your findings or if I can be of any further assistance please contact me.

INVOICE NUMBER

708



DATE

4/7/22

L.D. McGill, DVM, Ph.D., DACVP
8288 Top of the World Drive
Cottonwood Heights, UT 84121
ldmcgill.vetpath@gmail.com
cell: 801-865-1220

INTERPRETED BY

L.D. McGill, DVM,
Ph.D., DACVP

PATIENT

Cleo Kelly

SPECIES

Feline

BREED

DLH

SEX

Male Neutered

AGE

5y

WEIGHT

14.4

HOSPITAL NAME

Rotterdam Veterinary
Hospital

REFERRING VET

Dr. Scarpinato

INVOICE NUMBER

708