



DATE PRESENTING CLINICAL SIGNS

4/6/22

Patient presented for Routine Exam 4/6/22. Owner noticed mass on left caudal flank area, duration of mass unknown. Fine needle aspirate performed to obtain samples.

INTERPRETED BY

CYTOLOGY SUBMISSION

Skin mass

L.D. McGill, DVM,
Ph.D, DACVP

OBSERVATIONS

Skin mass: Submitted are 2 excellent videos of high magnification of cells collected from the skin mass on Bucky. Most of the cells on the videos demonstrate granularity of the cytoplasm. Granules are purple to metachromatic. Many of the cells are intermediately granulated. There appeared to be one or two eosinophils. There are free granules in the surrounding tissue. Occasional cells appeared to be multinucleated.

PATIENT

Bucky Younes

INTERPRETATION OF THE FINDINGS & FURTHER RECOMMENDATIONS

Skin mass - Mast cell tumor

SPECIES

Canine

COMMENTS

The cellularity is characteristic of mast cell tumor. With the irregular granularity and the suggestion of multinucleated cells, this growth is likely a high-grade or at least an intermediate grade mast cell tumor. Wide excision of the mass is encouraged. A follow-up biopsy and grading of the mass as well as determining margins would be encouraged. A guarded prognosis is always warranted with mast cell tumors. These growths can occur in other locations and even metastasize to the spleen and liver. If staging is desired, then aspiration of the spleen and liver is encouraged.

BREED

Stafford Terrier

SEX

Male

AGE

10y

WEIGHT

81.6

HOSPITAL NAME

Rotterdam Veterinary
Hospital

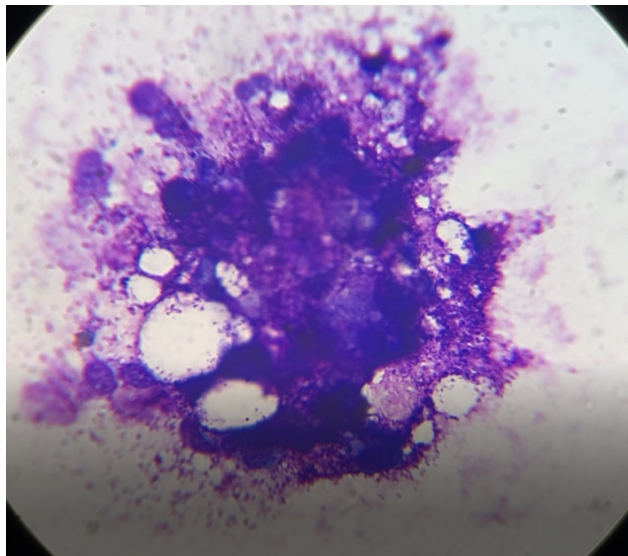


Image shows mast cells as a group or multinucleated tumor cells. The granules are diagnostic.

REFERRING VET

Dr. Kopa

The information and recommendations provided are based on the images presented by the referring veterinarian. No evaluation can be communicated regarding pathology that was not visible in the image/video clips provided.

Thank you for this referral. If the clinical or image interpretation does not parallel your findings or if I can be of any further assistance please contact me.

INVOICE NUMBER

707



DATE

4/6/22

L.D. McGill, DVM, Ph.D., DACVP
8288 Top of the World Drive
Cottonwood Heights, UT 84121
ldmcgill.vetpath@gmail.com
cell: 801-865-1220

INTERPRETED BY

L.D. McGill, DVM,
Ph.D., DACVP

PATIENT

Buckey Younes

SPECIES

Canine

BREED

Stafford Terrier

SEX

Male

AGE

10y

WEIGHT

81.6

HOSPITAL NAME

Rotterdam Veterinary
Hospital

REFERRING VET

Dr. Kopa

INVOICE NUMBER

707