



DATE PRESENTING CLINICAL SIGNS

4/4/23

8 years female spayed dog was presented with a complaint of having several lumps on the body from on left hindlimb and in left axillary region.

On palpation no signs of pain were observed. No discharges were oozing from these lumps. Lumps are not progressive and they are not increasing in size according to the owner.

INTERPRETED BY

CBC/Hematology & Serum Biochemistry profile was done
CBC/Hematology is having all normal parameters

L.D. McGill, DVM,
Ph.D, DACVP

PATIENT CYTOLOGY SUBMISSION

FNA of Dermal

Coco Srilekha

SPECIES OBSERVATIONS

Canine

Mass: Submitted are 5 images and a video of cells collected from a mass on Coco. The cellularity consists entirely of red blood cells with protein and some lipid. Nucleated cells are not identified. There is degenerate debris and there is stain precipitate. No other significant cellularity is identified.

BREED

Beagle

INTERPRETATION OF THE FINDINGS & FURTHER RECOMMENDATIONS

Mass - RBCs with protein and lipid and debris.

SEX COMMENTS

Female Spayed

The cellularity is entirely non-nucleated. Red blood cells are prominent. There is some protein and there is lipid. I wonder about the possibility of a lipoma with minimal release of cells. Another possibility would be some type of sarcoma, but multiple sarcomas are uncommon. This aspiration has collected no nucleated cells, at least in these images. There is prominent stained precipitate.

AGE

8 years

WEIGHT

16kg

HOSPITAL NAME

Pawsitive Veterinary
Clinic Dubai Silicon
Oasis

REFERRING VET

Dr. Hamza Arshad

INVOICE NUMBER

40697

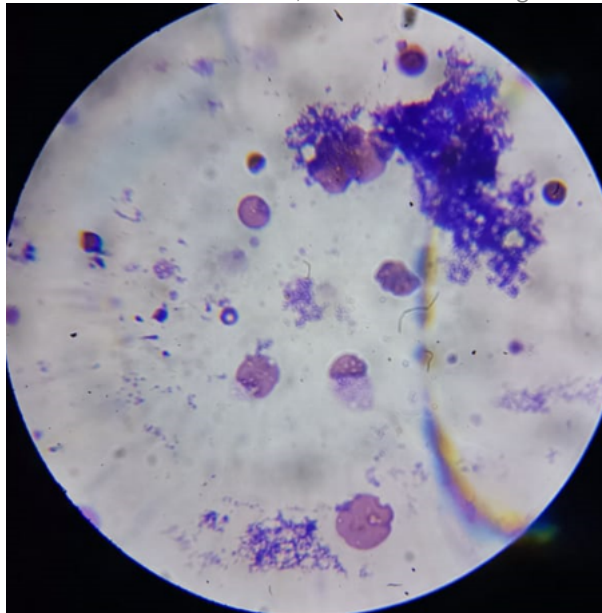


Image shows RBCs, lipid and protein collected from the mass on Coco. The dark blue material is stain precipitate. Nucleated cells were not identified.



DATE

4/4/23

The information and recommendations provided are based on the images presented by the referring veterinarian. No evaluation can be communicated regarding pathology that was not visible in the image/video clips provided.

INTERPRETED BY

L.D. McGill, DVM,
Ph.D, DACVP

Thank you for this referral. If the clinical or image interpretation does not parallel your findings or if I can be of any further assistance, please contact me.

PATIENT

Coco Srilekha

L.D. McGill, DVM, Ph.D., DACVP
8288 Top of the World Drive
Cottonwood Heights, UT 84121
ldmcgill.vetpath@gmail.com
cell: 801-865-1220

SPECIES

Canine

BREED

Beagle

SEX

Female Spayed

AGE

8 years

WEIGHT

16kg

HOSPITAL NAME

Pawsitive Veterinary
Clinic Dubai Silicon
Oasis

REFERRING VET

Dr. Hamza Arshad

INVOICE NUMBER

40697