



DATE PRESENTING CLINICAL SIGNS
4/4/22 Allergies. Enlarged iliac and pop In

CYTOLOGY SUBMISSION
Lymph node

INTERPRETED BY

L.D. McGill, DVM,
Ph.D, DACVP

OBSERVATIONS

Lymph node: Submitted are 2 excellent videos of very good collections of cells from the popliteal lymph node in Lilly. The cellularity is mixed. There are large numbers of small mature lymphocytes throughout the smears. There are scattered large cells but they are few. Plasma cells are readily identified. Neutrophils are easily identified. The lymphocytes have nuclei that are approximately the size of red blood cells and thus they are mature small cells. There are scattered eosinophils in the collection.

PATIENT

Lilly Ritter

INTERPRETATION OF THE FINDINGS & FURTHER RECOMMENDATIONS

Lymph node - Chronic suppurative lymphadenitis with plasma cells and secondary eosinophilic infiltration.

SPECIES

Canine

COMMENTS

The changes in this collection of videos support a chronic inflammatory process. The plasma cells suggest an antigenic response in these lymph nodes. The eosinophils are consistent with the allergic process you have described. These changes are not characteristic of malignancy. I did not identify large cells with prominent nucleoli. The small cells appeared to be within normal limits with respect to small mature lymphocytes. The cause for the antigenic response is not identified but is likely some type of systemic inflammatory response. Again there is no suggestion of malignancy in this collection.

BREED

Labrador Retriever

SEX

Female Spayed

AGE

9y

WEIGHT

80

HOSPITAL NAME

Bayshore Veterinary
Hospital

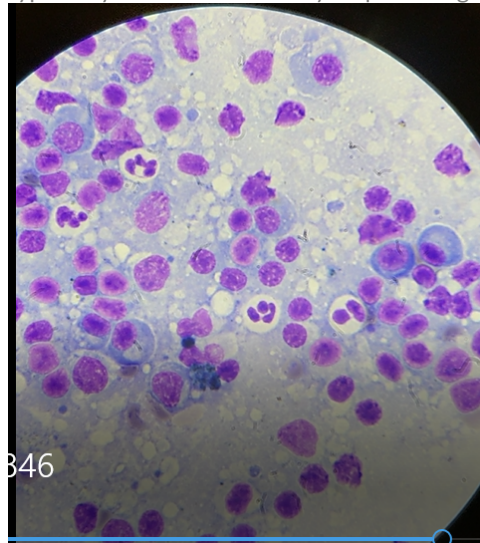


Image shows cells collected from the lymph node in Lilly. Note the plasma cells and neutrophils. The majority of the cells are small mature lymphocytes.

REFERRING VET

Dr. Hunt

The information and recommendations provided are based on the images presented by the referring veterinarian. No evaluation can be communicated regarding pathology that was not visible in the image/video clips provided.

Thank you for this referral. If the clinical or image interpretation does not parallel your findings or if I can be of any further assistance please contact me.

INVOICE NUMBER

705



DATE

4/4/22 **L.D. McGill, DVM, Ph.D., DACVP**
8288 Top of the World Drive
Cottonwood Heights, UT 84121
ldmcgill.vetpath@gmail.com
cell: 801-865-1220

INTERPRETED BY

L.D. McGill, DVM,
Ph.D, DACVP

PATIENT

Lilly Ritter

SPECIES

Canine

BREED

Labrador Retriever

SEX

Female Spayed

AGE

9y

WEIGHT

80

HOSPITAL NAME

Bayshore Veterinary
Hospital

REFERRING VET

Dr. Hunt

INVOICE NUMBER

705