



DATE PRESENTING CLINICAL SIGNS

4/4/22

Patient has a history of a 5mm mast cell tumor over base of tail, mass was not present during exam 4/4/22. New 3cm diffuse, cutaneous swelling found at caudal sternum. Swelling was aspirated 4/4/22 and videos of aspirates are attached.

INTERPRETED BY CYTOLOGY SUBMISSION

L.D. McGill, DVM,
Ph.D, DACVP

Dermal lesion

PATIENT

Jude Belanger

OBSERVATIONS

Dermal lesion: Submitted are 3 excellent videos of moderate cellular collections from the dermal mass on Jude. The nucleated cellularity is minimal to moderate. There are packets and individualized cells with purple to metachromatic granules. The cells are mast cells. Eosinophils are readily identified with a very few neutrophils. The mast cells in general appear to be moderately to well granulated.

INTERPRETATION OF THE FINDINGS & FURTHER RECOMMENDATIONS

Dermal lesion - Mast cell tumor.

SPECIES

Canine

COMMENTS

The cellularity is definitely that of a mast cell tumor. The granularity of the cells suggest low to intermediate grade mast cell tumor. Excision of the lesion is expected to result in a favorable prognosis. This breed of dog will often have multiple low-grade mast cell tumors over its lifetime. Excision does not have to be wide but needs to be complete. A favorable prognosis will often occur with complete excision of a low-grade mast cell tumor in this breed. Continued monitoring of Jude for independent growths in other locations in the skin is encouraged.

BREED

Pug

SEX

Male

AGE

13y

WEIGHT

21.7#

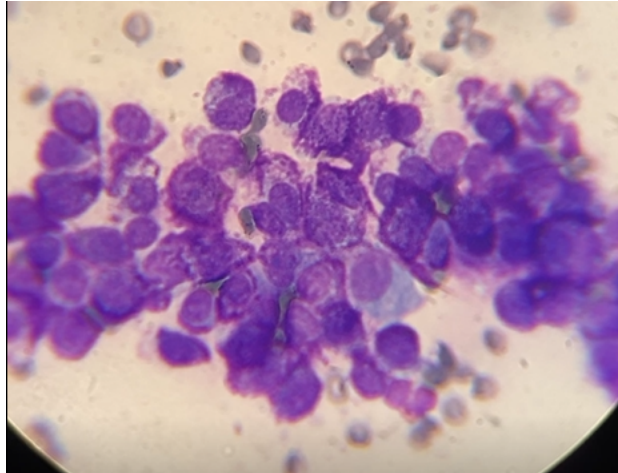


Image shows a group of mast cells with good granularity to the cytoplasm collected from the lesion on Jude. Eosinophils are also present in the smears.

HOSPITAL NAME

Rotterdam Veterinary
Hospital

The information and recommendations provided are based on the images presented by the referring veterinarian. No evaluation can be communicated regarding pathology that was not visible in the image/video clips provided.

REFERRING VET

Dr. McNulty

Thank you for this referral. If the clinical or image interpretation does not parallel your findings or if I can be of any further assistance please contact me.

INVOICE NUMBER

704



DATE L.D. McGill, DVM, Ph.D., DACVP
8288 Top of the World Drive
Cottonwood Heights, UT 84121
ldmcgill.vetpath@gmail.com
cell: 801-865-1220

INTERPRETED BY

L.D. McGill, DVM,
Ph.D., DACVP

PATIENT

Jude Belanger

SPECIES

Canine

BREED

Pug

SEX

Male

AGE

13y

WEIGHT

21.7#

HOSPITAL NAME

Rotterdam Veterinary
Hospital

REFERRING VET

Dr. McNulty

INVOICE NUMBER

704