



**DATE PRESENTING CLINICAL SIGNS**

4/30/22

Bilaterally swollen hocks; US showed mild bilateral tarsocrural joint arthritis with mild effusion and synovialitis and periarticular bone remodeling. R/O immune mediated arthropathy (most likely since bilateral) vs infectious, traumatic, degenerative. FNA of right hock joint

**INTERPRETED BY CYTOLOGY SUBMISSION**

Joint fluid

L.D. McGill, DVM,  
Ph.D, DACVP

**OBSERVATIONS**

Joint fluid: Submitted are 3 images and many videos of cells collected from the joint on Laoghaire. The cellularity is minimal throughout most of the videos and images. There are scattered neutrophils and lymphocytes and scattered synovial cells. There is prominent synovial fluid which is myxomatous throughout the collection. Bacterial organisms or other causes for inflammatory cell accumulation are not identified in the collection.

**PATIENT**

Laoghaire Slezak

**INTERPRETATION OF THE FINDINGS & FURTHER RECOMMENDATIONS**

**SPECIES** Joint fluid - Minimal cellularity with mixed cell collection.

Canine

**COMMENTS**

The cellularity in this collection is minimal and mixed. This cellularity is not consistent with immune mediated synovitis in the dog. Most commonly those cells are neutrophils and they are quite prominent throughout the collection. There is no suggestion of sepsis nor is there evidence of any other specific primary synovial response. The changes in this collection suggest degenerative joint disease or trauma or the possibility of tick borne infectious disease including Lyme disease. Continued evaluation for other etiologic agents is encouraged.

**BREED**

Golden Retriever

**SEX**

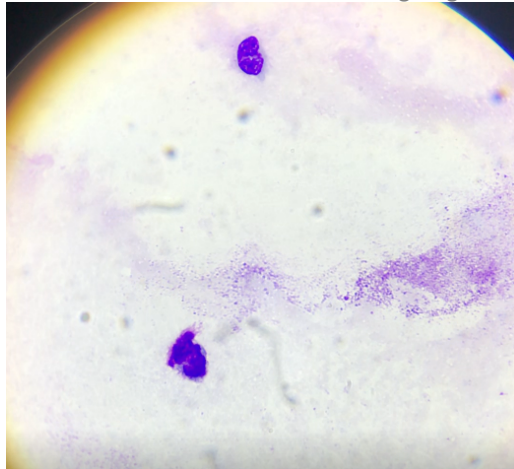
Female Intact

**AGE**

2y

**WEIGHT**

73 lbs



**HOSPITAL NAME**

Rockaway Animal  
Hospital

Image shows a couple of the cells collected from the synovial fluid from Laoghaire. There are few cells with a neutrophil and possible lymphocyte.

**The information and recommendations provided are based on the images presented by the referring veterinarian. No evaluation can be communicated regarding pathology that was not visible in the image/video clips provided.**

**REFERRING VET**

Dr. Maniar

Thank you for this referral. If the clinical or image interpretation does not parallel your findings or if I can be of any further assistance please contact me.

**INVOICE NUMBER**

727



**DATE** L.D. McGill, DVM, Ph.D., DACVP

4/30/22  
8288 Top of the World Drive  
Cottonwood Heights, UT 84121  
ldmcgill.vetpath@gmail.com  
cell: 801-865-1220

**INTERPRETED BY**

L.D. McGill, DVM,  
Ph.D, DACVP

**PATIENT**

Laoghaire Slezak

**SPECIES**

Canine

**BREED**

Golden Retriever

**SEX**

Female Intact

**AGE**

2y

**WEIGHT**

73 lbs

**HOSPITAL NAME**

Rockaway Animal  
Hospital

**REFERRING VET**

Dr. Maniar

**INVOICE NUMBER**

727