



**DATE PRESENTING CLINICAL SIGNS**

4/30/22

Elev liver enzymes, inappetent; has been tx with IV fluids, Clavacillin, mirtazapine, Cerenia, Vit B injection, Denamarin (which seems to make her vomit; owner unable to give) . Symptoms started early April with decrease appetite, licking lips  
Mostly indoor, outside a little under supervision; no prior health history

**INTERPRETED BY**

CBC normal

L.D. McGill, DVM,  
Ph.D, DACVP

Chems: elev ALT 592, ALKP 324, TBil 1.0, Chol 251, BUN low 9, else normal including Spec fPL.  
Pretty unremarkable PE; Mild elev temp, soft parasternal systolic murmur

**CYTOLOGY SUBMISSION**

Liver

**PATIENT**

Katy Carls

**OBSERVATIONS**

Liver: Submitted are 5 excellent videos of excellent collections of hepatocytes from the liver in Katy. All of the hepatocytes are demonstrating variable vacuoles in the cytoplasm. Lipid is prominent in the surrounding fluid. There are scattered inflammatory cells in the surrounding red blood cells. Malignant characteristics or sepsis are not identified.

**SPECIES**

Feline

**INTERPRETATION OF THE FINDINGS & FURTHER RECOMMENDATIONS**

Liver - Moderate to marked hepatocellular vacuolization consistent with feline fatty liver syndrome with mild inflammation.

**BREED**

DSH

**COMMENTS**

These cellular changes in these excellent collections of hepatocytes are most consistent with lipidosis and feline fatty liver syndrome. There are no other changes to suggest other pathology in this liver collection. Feline fatty liver syndrome is commonly associated with pancreatitis or enteritis. Other specific changes are not identified. Continued evaluation of other organs in the abdominal cavity is encouraged. A guarded prognosis is warranted unless re-alimentation is successful.

**SEX**

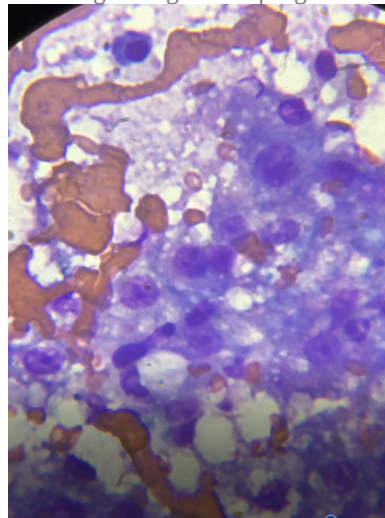
Female Spayed

**AGE**

10y

**WEIGHT**

4.4 kg



**HOSPITAL NAME**

Skagit Animal Clinic

**REFERRING VET**

Dr. Sandors

Image shows lipid and vacuoles in hepatocytes collected from Katy. These changes are characteristic of feline fatty liver.

The information and recommendations provided are based on the images presented by the referring veterinarian. No evaluation can be communicated regarding pathology that was not visible in the image/video clips provided.

**INVOICE NUMBER**

725



**DATE** 4/30/22 Thank you for this referral. If the clinical or image interpretation does not parallel your findings or if I can be of any further assistance please contact me.

**INTERPRETED BY** L.D. McGill, DVM, Ph.D., DACVP  
8288 Top of the World Drive  
Cottonwood Heights, UT 84121  
ldmcgill.vetpath@gmail.com  
cell: 801-865-1220

**PATIENT**

Katy Carls

**SPECIES**

Feline

**BREED**

DSH

**SEX**

Female Spayed

**AGE**

10y

**WEIGHT**

4.4 kg

**HOSPITAL NAME**

Skagit Animal Clinic

**REFERRING VET**

Dr. Sanders

**INVOICE NUMBER**

725