

DATE PRESENTING CLINICAL SIGNS

4/29/22

Diffuse pulmonary nodules- R/O fungal vs neoplasia. FNA performed of pulmonary nodule. C&S is also being performed.

INTERPRETED BY

CYTOLOGY SUBMISSION

Lung

L.D. McGill, DVM,
Ph.D, DACVP

OBSERVATIONS

PATIENT

Zoe Bocchino

Lung: Submitted are 8 excellent videos of moderate to excellent collections of cells from the nodules in the lung in Zoe. The cellularity is mixed. There are large numbers of macrophages, most of which have a foamy cytoplasm. There are some granules in the cytoplasm but this appears to be degenerate debris. There are scattered neutrophils and scattered lymphocytes. Malignant characteristics are not identified. I did not identify structures suggestive of histoplasma or blastomyces. There were some structures that could have been fungal hyphae associated with some foreign material. There was a structure which could be a hair shaft and some keratinized cells. My concern is that these could be contaminants or primary.

SPECIES

Canine

INTERPRETATION OF THE FINDINGS & FURTHER RECOMMENDATIONS

BREED

Pitt Bull Terrier

Lung - Chronic pyogranulomatous inflammation with a suggestion of foreign material and possible fungal hyphae.

SEX

Female Intact

The cellularity does not support neoplasia but there is prominent evidence of chronic inflammation. This chronic inflammation could be the result of aspiration of this foreign material which included what appeared to be a hair shaft in one location and possibly keratinized structures in others. Those could also be contaminants from the surface. There were some structures that could be fungal hyphae suggesting possible aspergillosis or candida. Treatment for inflammation and possible fungal infection is encouraged. A guarded prognosis is warranted due to the chronicity and prominent inflammatory process.

AGE

4.5 months

The cellularity does not support neoplasia but there is prominent evidence of chronic inflammation. This chronic inflammation could be the result of aspiration of this foreign material which included what appeared to be a hair shaft in one location and possibly keratinized structures in others. Those could also be contaminants from the surface. There were some structures that could be fungal hyphae suggesting possible aspergillosis or candida. Treatment for inflammation and possible fungal infection is encouraged. A guarded prognosis is warranted due to the chronicity and prominent inflammatory process.

WEIGHT

38 lbs

HOSPITAL NAME

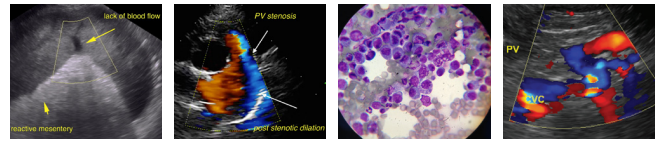
All Creatures Great and
Small Denville

REFERRING VET

Dr. Ashmore

INVOICE NUMBER

624



DATE

4/29/22

INTERPRETED BY

L.D. McGill, DVM,
Ph.D., DACVP

PATIENT

Zoe Bocchino

SPECIES

Canine

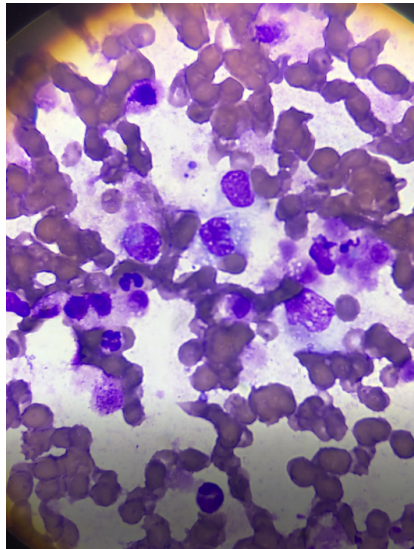


Image shows a representative collection of cells from the lung in Zoe. The large cells macrophages with foamy cytoplasm. There are scattered neutrophils in this field.

BREED

Pitt Bull Terrier

The information and recommendations provided are based on the images presented by the referring veterinarian. No evaluation can be communicated regarding pathology that was not visible in the image/video clips provided.

SEX

Female Intact

Thank you for this referral. If the clinical or image interpretation does not parallel your findings or if I can be of any further assistance please contact me.

AGE

4.5 months

L.D. McGill, DVM, Ph.D., DACVP
8288 Top of the World Drive
Cottonwood Heights, UT 84121
ldmcgill.vetpath@gmail.com
cell: 801-865-1220

WEIGHT

38 lbs

HOSPITAL NAME

All Creatures Great and
Small Denville

REFERRING VET

Dr. Ashmore

INVOICE NUMBER

624