



DATE PRESENTING CLINICAL SIGNS

4/28/22 Alt 375

CYTOLOGY SUBMISSION

Liver

INTERPRETED BY

L.D. McGill, DVM,
Ph.D, DACVP

OBSERVATIONS

Liver: Submitted are 3 excellent videos of minimal to moderate collections of cells from the liver in Percy. The hepatocytes demonstrate vacuolization and slight granularity of the cytoplasm. There are scattered mononuclear cells interspersed throughout the red blood cells associated with the hepatocytes. Malignant characteristics are not confirmed. The vacuolization and granularity of the hepatocytes appears to be the major process available to confirm in these collections.

PATIENT

Percy Ball

INTERPRETATION OF THE FINDINGS & FURTHER RECOMMENDATIONS

Liver - Hepatocellular vacuolization and granularity with the possibility of nodular hyperplasia.

SPECIES

Canine

COMMENTS

The cellularity in this collection has several packets of hepatocytes but there are many fields without hepatocytes. The aggregates that you spent time on may have been vacuolated hepatocytes but I cannot confirm that observation. With the cells available to evaluate, nodular hyperplasia appears to be most likely. A low-grade hepatocellular adenoma can be suggested. Other types of neoplasia or hepatocellular carcinoma are not identifiable in this collection. Biopsy of the region will be required to confirm the process but cytologically it appears to be low-grade or benign.

BREED

Cav

SEX

Male Neutered

AGE

10y

WEIGHT

25 lbs

HOSPITAL NAME

Bayshore Veterinary
Hospital

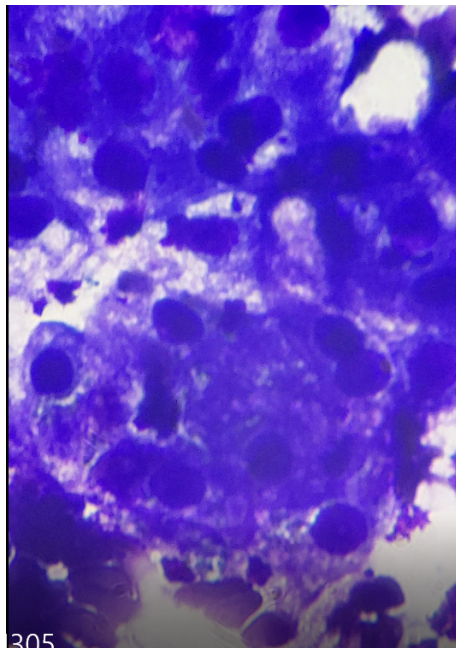


Image shows a good group of hepatocytes with vacuolization collected from Percy. I was unable to confirm neoplasia.

REFERRING VET

Dr. Hunt

INVOICE NUMBER

622



DATE 4/28/22 The information and recommendations provided are based on the images presented by the referring veterinarian. No evaluation can be communicated regarding pathology that was not visible in the image/video clips provided.

INTERPRETED BY L.D. McGill, DVM, Ph.D., DACVP Thank you for this referral. If the clinical or image interpretation does not parallel your findings or if I can be of any further assistance please contact me.

L.D. McGill, DVM,
Ph.D., DACVP

L.D. McGill, DVM, Ph.D., DACVP
8288 Top of the World Drive
Cottonwood Heights, UT 84121
ldmcgill.vetpath@gmail.com
cell: 801-865-1220

PATIENT
Percy Ball

SPECIES
Canine

BREED
Cav

SEX
Male Neutered

AGE
10y

WEIGHT
25 lbs

HOSPITAL NAME
Bayshore Veterinary
Hospital

REFERRING VET
Dr. Hunt

INVOICE NUMBER
622