



DATE PRESENTING CLINICAL SIGNS

4/28/22

Bloated Abdomen; Feels fine otherwise.
Ascites present; Fluid has TP of 3.0 and scant numbers of mesothelial type cells. On U/S the spleen is enlarged and irregular. The Liver is also enlarged.
HCT of 15% w/ 2.5% Retics; Platelets were slightly low.

INTERPRETED BY

L.D. McGill, DVM,
Ph.D, DACVP

CYTOLOGY SUBMISSION

Spleen

PATIENT

Gizmo Simpson

OBSERVATIONS

Spleen: Submitted are 8 excellent videos of excellent collections of cells from the spleen in Gizmo. The cellularity is mixed with a preponderance of round cells and macrophages. There are scattered neutrophils and eosinophils. The macrophages have a foamy vacuolated cytoplasm and occasionally are phagocytosing RBCs. The round cells are lymphocytes that are demonstrating anisocytosis and anisokaryosis with prominent nucleoli in the nuclei. The nucleoli are varied. The cytoplasm is minimal and dark bluish gray. Some of these cells are quite large.

SPECIES

Feline

INTERPRETATION OF THE FINDINGS & FURTHER RECOMMENDATIONS

Spleen - Round cell tumor with large numbers of atypical lymphoid cells suggestive of lymphoma and prominent macrophages.

BREED

DSH

COMMENTS

This excellent collection demonstrates many characteristics that are suggestive of an aggressive lymphoma in Gizmo. The macrophages are markedly stimulated and appear to be markedly reactive. My concern is that this is a lymphoma with a phagocytic histiocytic process in the spleen. These slides can be sent out for immunophenotyping by PARR. This should assist in confirming the diagnosis and hopefully the cell type. Splenectomy with a follow biopsy may be beneficial in confirming the specific diagnosis. A guarded to unfavorable prognosis is warranted, in my opinion.

SEX

Male Neutered

AGE

10y

WEIGHT

15 lbs

HOSPITAL NAME

Franklin Animal Clinic

REFERRING VET

Dr. Doverspike

INVOICE NUMBER

621

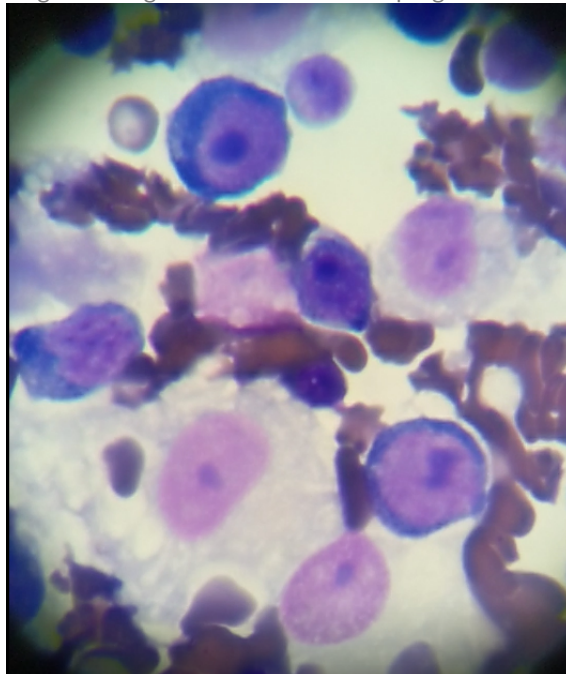


Image shows some of the lymphoid cells with irregular nucleoli and a group of macrophages. This is an unusual combination of cells.



DATE

4/28/22

The information and recommendations provided are based on the images presented by the referring veterinarian. No evaluation can be communicated regarding pathology that was not visible in the image/video clips provided.

INTERPRETED BY

L.D. McGill, DVM,
Ph.D, DACVP

Thank you for this referral. If the clinical or image interpretation does not parallel your findings or if I can be of any further assistance please contact me.

PATIENT

Gizmo Simpson

L.D. McGill, DVM, Ph.D., DACVP
8288 Top of the World Drive
Cottonwood Heights, UT 84121
ldmcgill.vetpath@gmail.com
cell: 801-865-1220

SPECIES

Feline

BREED

DSH

SEX

Male Neutered

AGE

10y

WEIGHT

15 lbs

HOSPITAL NAME

Franklin Animal Clinic

REFERRING VET

Dr. Doverspike

INVOICE NUMBER

621