



DATE PRESENTING CLINICAL SIGNS

4/22/22

Cavitated mass in spleen found on ultrasound.

CYTOLOGY SUBMISSION

FNA of Spleen

INTERPRETED BY

L.D. McGill, DVM,
Ph.D, DACVP

OBSERVATIONS

Spleen: Submitted are 8 excellent videos of moderate collections of cells from the spleen in Chase. There are large numbers of red blood cells throughout the smears. In the first video, there is an aggregate of cells that appear to be slightly elongated with markedly varied nuclei. There appears to be one extremely large cell in the field. In the rest of the videos, there are large numbers of inflammatory cells that are mixed including neutrophils, lymphocytes and rare nucleated RBCs. Inflammation is very prominent in the majority of the fields.

PATIENT

Chase Hasbrouck

INTERPRETATION OF THE FINDINGS & FURTHER RECOMMENDATIONS

Spleen - One field with apparent atypical spindloid cells with chronic inflammation throughout most videos.

SPECIES

Canine

COMMENTS

The group of irregular cells with the very large nucleus in one cell strongly suggests some type of sarcoma. With the cavitated appearance of the lesion in the spleen and even this small number of cells, hemangiosarcoma must be considered as a likely diagnosis. There is extensive inflammation which could accompany a hemangiosarcoma or any type of splenic process. Splenectomy with a follow-up biopsy is encouraged. If the lesion can be limited to the spleen, then prolonging the life in Chase is very possible. There is always a concern that this growth could be metastatic either from the spleen or from other locations to the spleen. A guarded prognosis is definitely warranted.

BREED

shetland sheepdog

SEX

Male Neutered

AGE

13y

WEIGHT

41lbs

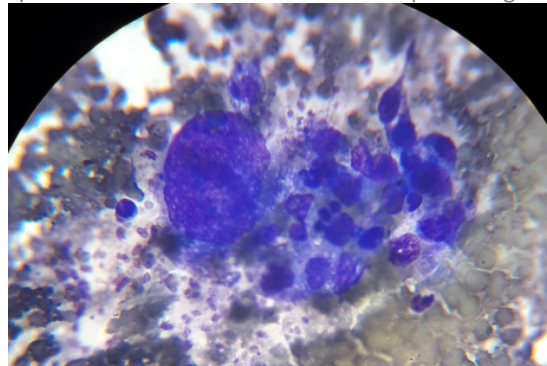


Image shows a group of irregular cells with some spindle cell formation and one very large cell collected from the spleen in Chase. Inflammation was observed in most other fields.

HOSPITAL NAME

Rotterdam Veterinary
Hospital

The information and recommendations provided are based on the images presented by the referring veterinarian. No evaluation can be communicated regarding pathology that was not visible in the image/video clips provided.

Thank you for this referral. If the clinical or image interpretation does not parallel your findings or if I can be of any further assistance, please contact me.

REFERRING VET

Dr. Anna St Sir

L.D. McGill, DVM, Ph.D., DACVP

8288 Top of the World Drive
Cottonwood Heights, UT 84121
ldmcgill.vetpath@gmail.com

INVOICE NUMBER

40509

cell: 801-865-1220



DATE

4/22/22

INTERPRETED BY

L.D. McGill, DVM,
Ph.D, DACVP

PATIENT

Chase Hasbrouck

SPECIES

Canine

BREED

shetland sheepdog

SEX

Male Neutered

AGE

13y

WEIGHT

41lbs

HOSPITAL NAME

Rotterdam Veterinary
Hospital

REFERRING VET

Dr. Anna St Sir

INVOICE NUMBER

40509