



DATE PRESENTING CLINICAL SIGNS

4/20/23

1cm X1.5cm nodule at 7 o'clock position of the rectum. Mass near edge f mass in 5 cm from rectum

CYTOLOGY SUBMISSION

Mass near rectum

INTERPRETED BY

L.D. McGill, DVM,
Ph.D, DACVP

OBSERVATIONS

Mass near rectum: Submitted are 8 excellent images of excellent collections of cells from the mass near the rectum on Stoney. The cellularity is characteristic with large numbers of round cells most of which have metachromatic or purple granules in their cytoplasm. Some of these cells are poorly granulated and some are irregularly granulated. There are scattered inflammatory cells mixed throughout the collection but these well granulated mast cells are the prominent cellularity. In this instance, the cells are rather well granulated for the most part.

PATIENT

Stoney Waffle

INTERPRETATION OF THE FINDINGS & FURTHER RECOMMENDATIONS

Mass near the rectum - Mast cell tumor

SPECIES

Canine

COMMENTS

These excellent images show large numbers of mast cells and the mast cells appear to be well granulated. There is speculation that when the cells are well granulated in the cytologic collection, they are low grade. This growth would be a low-grade mast cell tumor or likely grade 1 or grade 2 in some of the categories. Mast cell tumors always require a guarded prognosis. In this location, surgical intervention will certainly be difficult but is a potential for therapy. Using chemotherapy in this case may be beneficial. A guarded prognosis is still warranted.

BREED

Staffordshire

SEX

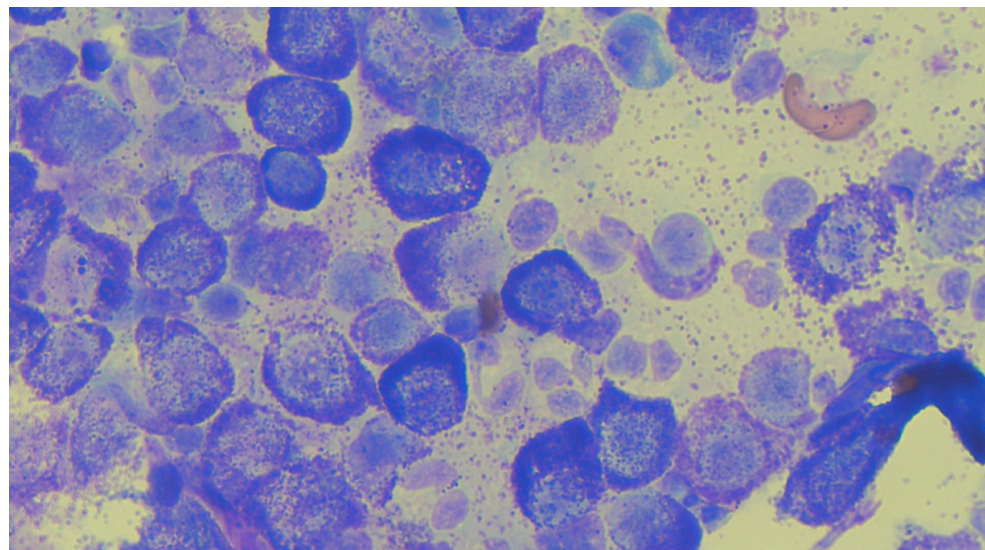
M

AGE

6

WEIGHT

43



HOSPITAL NAME

Torch Lake Veterinary
Clinic

This image shows the mast cells in this collection from the mass on Stoney. Note the irregular granularity. Inflammatory cells are scattered throughout and some appear to be eosinophils.

REFERRING VET

Dr. Waffle

The information and recommendations provided are based on the images presented by the referring veterinarian. No evaluation can be communicated regarding pathology that was not visible in the image/video clips provided.

Thank you for this referral. If the clinical or image interpretation does not parallel your findings or if I can be of any further assistance please contact me.

INVOICE NUMBER

936



DATE

4/20/23

L.D. McGill, DVM, Ph.D., DACVP
8288 Top of the World Drive
Cottonwood Heights, UT 84121
ldmcgill.vetpath@gmail.com
cell: 801-865-1220

INTERPRETED BY

L.D. McGill, DVM,
Ph.D., DACVP

PATIENT

Stoney Waffle

SPECIES

Canine

BREED

Staffordshire

SEX

M

AGE

6

WEIGHT

43

HOSPITAL NAME

Torch Lake Veterinary
Clinic

REFERRING VET

Dr. Waffle

INVOICE NUMBER

936