



DATE PRESENTING CLINICAL SIGNS

4/2/22

Coughing, resp distress

CYTOLOGY SUBMISSION

Coughed up material

INTERPRETED BY

L.D. McGill, DVM,
Ph.D, DACVP

OBSERVATIONS

Coughed up material: Submitted are several excellent videos of minimal to moderate collections of cells from the coughed up material from Ryn. These cells are almost all keratinized squamous cells interspersed with bacteria. The bacteria are rod shaped with many structures demonstrating palisading patterns. They have been termed as railroad tie patterns. These are characteristic structures from the pharynx.

PATIENT

Ryn Rachuy

INTERPRETATION OF THE FINDINGS & FURTHER RECOMMENDATIONS

Coughed up material - Pharyngeal collection with Simonsiella and bacteria.

SPECIES COMMENTS

Canine

The collection demonstrates a common pharyngeal collection of bacteria in Simonsiella. This collection is not from the deep lung location. There are no fungal organisms or neoplastic cells in the collection. A repeat BAL is encouraged. This will collect cells from the deep pulmonary region. Hopefully this is helpful information to further work up the pulmonary problem in Ryn.

BREED

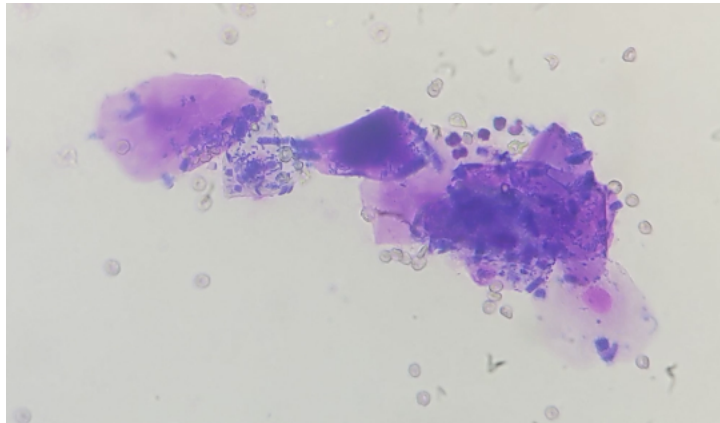
Doberman

SEX

Female

AGE

3y



WEIGHT

80

Image shows keratinized cells with Simonsiella and bacteria collected from Ryn. There are no neoplastic cells or fungi.

The information and recommendations provided are based on the images presented by the referring veterinarian. No evaluation can be communicated regarding pathology that was not visible in the image/video clips provided.

HOSPITAL NAME

Bayshore Veterinary
Hospital

Thank you for this referral. If the clinical or image interpretation does not parallel your findings or if I can be of any further assistance please contact me.

REFERRING VET

Dr. Hunt

L.D. McGill, DVM, Ph.D., DACVP
8288 Top of the World Drive
Cottonwood Heights, UT 84121
ldmcgill.vetpath@gmail.com
cell: 801-865-1220

INVOICE NUMBER

703



DATE

4/2/22

INTERPRETED BY

L.D. McGill, DVM,
Ph.D, DACVP

PATIENT

Ryn Rachuy

SPECIES

Canine

BREED

Doberman

SEX

Female

AGE

3y

WEIGHT

80

HOSPITAL NAME

Bayshore Veterinary
Hospital

REFERRING VET

Dr. Hunt

INVOICE NUMBER

703