



DATE PRESENTING CLINICAL SIGNS

4/19/22 FNA: Liver. ULTRASONOGRAPHIC FINDINGS
Geriatric abdomen with undefined hepatic nodule. If any weight loss is present FNA is indicated or if liver enzyme elevations are present.
Nodular hyperplasia, abscessation and round cell neoplasia are all possible.

INTERPRETED BY

L.D. McGill, DVM,
Ph.D, DACVP

CYTOLOGY SUBMISSION

Liver

OBSERVATIONS

Liver: Submitted are 3 excellent videos of minimal to moderate cellular collections from the liver in Archie. Where the hepatocytes are present, they demonstrate mild vacuolization and granularity. The vacuolization is irregular. The surrounding red blood cells include a mixture of a few inflammatory cells including lymphocytes and neutrophils. Malignant cellularity is not identified in the collection.

PATIENT

Archie Grillo

INTERPRETATION OF THE FINDINGS & FURTHER RECOMMENDATIONS

SPECIES Liver - Mild diffuse hepatocellular vacuolization and granularity with mild inflammation.

Feline

COMMENTS

The changes in this liver appear to be secondary changes of a nonspecific nature. The vacuolization could be the result of early feline fatty liver syndrome. These changes can be secondary to pancreatitis or enteritis. There is evidence of mild inflammation in the red blood cells submitted. There is no suggestion of malignancy or sepsis. Primary hepatic change is not identified.

BREED

DSH

SEX

Male Neutered

AGE

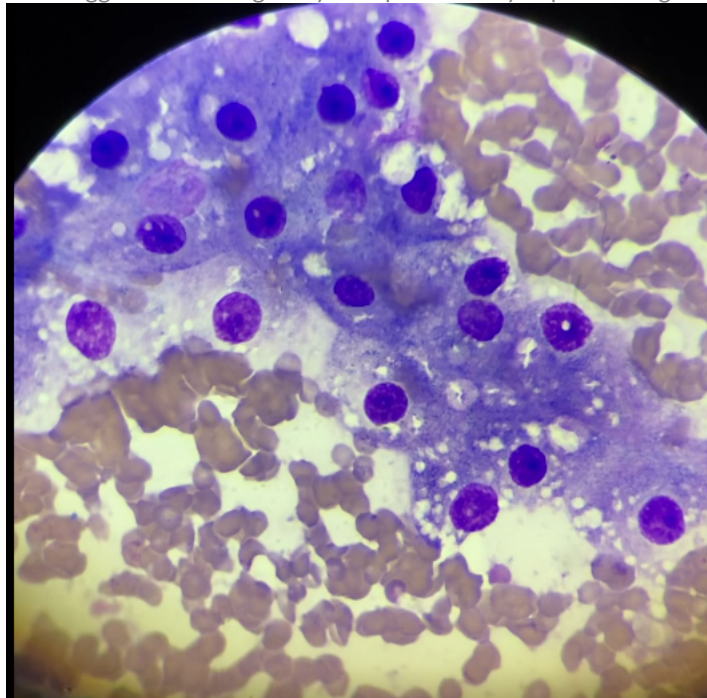
12y

WEIGHT

10 lbs

HOSPITAL NAME

Rockaway Animal
Hospital



REFERRING VET

Dr. Maniar

Image shows a group of hepatocytes with mild vacuolization collected from Archie. Primary liver changes are not identified.

INVOICE NUMBER

716



DATE

4/19/22

The information and recommendations provided are based on the images presented by the referring veterinarian. No evaluation can be communicated regarding pathology that was not visible in the image/video clips provided.

INTERPRETED BY

L.D. McGill, DVM,
Ph.D., DACVP

Thank you for this referral. If the clinical or image interpretation does not parallel your findings or if I can be of any further assistance please contact me.

PATIENT

Archie Grillo

L.D. McGill, DVM, Ph.D., DACVP
8288 Top of the World Drive
Cottonwood Heights, UT 84121
ldmcgill.vetpath@gmail.com
cell: 801-865-1220

SPECIES

Feline

BREED

DSH

SEX

Male Neutered

AGE

12y

WEIGHT

10 lbs

HOSPITAL NAME

Rockaway Animal
Hospital

REFERRING VET

Dr. Maniar

INVOICE NUMBER

716