



DATE **PRESENTING CLINICAL SIGNS**
4/18/23 large solitary midabdominal lymph node adjacent to ICCJ. About 5.6cm x 3.8cm.
FNA performed.

INTERPRETED BY **CYTOLOGY SUBMISSION**
Abdominal mass

L.D. McGill, DVM,
Ph.D, DACVP

OBSERVATIONS

Abdominal mass: Submitted are 3 excellent videos of excellent collections of cells from this abdominal mass in the abdomen in Dude. The cellularity consists of packets of cells that are aggregated in irregular patterns throughout these videos. Occasionally these cells appear to be attempting to form acinar structures but the majority of the cells are vacuolated and granulated. There is definite anisokaryosis and anisocytosis. The aggregates are rather irregular but uniform throughout all of the videos. All of these aggregates have an epithelial cell pattern.

PATIENT

Dude Murphy

INTERPRETATION OF THE FINDINGS & FURTHER RECOMMENDATIONS

SPECIES Abdominal mass - Characteristic of a carcinoma

Feline

COMMENTS

The cellularity in this collection is characteristic of a carcinoma. The specific cell of origin is difficult to identify. Some of the cells are vacuolated causing concern about a secretory epithelial source but they could also be an intestinal source. In one or two areas, the cells even have the appearance of a neuroendocrine pattern of growth. I suspect that this is some type of carcinoma but the specific source will require surgical intervention and biopsy. There were few lymphoid cells in the surrounding red blood cells which suggests that this mass may in fact be within the lymph node and if so then it is likely metastatic. An unfavorable prognosis is warranted, in my opinion but surgical intervention and excision may prolong life in Dude.

BREED

DSH

SEX

Male Neutered

AGE

12y

WEIGHT

n/a

HOSPITAL NAME

Animal Care Centers
Flanders

REFERRING VET

Dr. Hallihan

INVOICE NUMBER

934

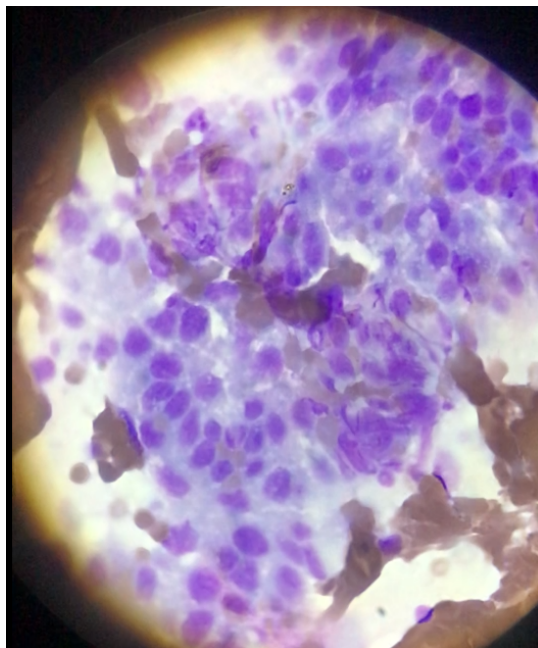


Image shows a group of cells collected from the abdominal mass in Dude. Note the anisokaryosis and chain-like pattern of growth.



DATE 4/18/23 The information and recommendations provided are based on the images presented by the referring veterinarian. No evaluation can be communicated regarding pathology that was not visible in the image/video clips provided.

INTERPRETED BY L.D. McGill, DVM, Ph.D., DACVP Thank you for this referral. If the clinical or image interpretation does not parallel your findings or if I can be of any further assistance please contact me.

L.D. McGill, DVM,
Ph.D., DACVP

L.D. McGill, DVM, Ph.D., DACVP
8288 Top of the World Drive
Cottonwood Heights, UT 84121
ldmcgill.vetpath@gmail.com
cell: 801-865-1220

PATIENT

Dude Murphy

SPECIES

Feline

BREED

DSH

SEX

Male Neutered

AGE

12y

WEIGHT

n/a

HOSPITAL NAME

Animal Care Centers
Flanders

REFERRING VET

Dr. Hallihan

INVOICE NUMBER

934