



DATE PRESENTING CLINICAL SIGNS

4/18/22

Hx of consistent GGT elevation and vomiting. slightly enlarged and uniform spleen at 1.0 cm with scalloping contour. FNA of spleen performed 25 g needle.

INTERPRETED BY

CYTOLOGY SUBMISSION

FNA of Spleen

L.D. McGill, DVM,
Ph.D, DACVP

OBSERVATIONS

Spleen: Submitted are 5 excellent videos of moderate collections of cells from the spleen in Bluebell. The cellularity is mixed throughout these videos. There are scattered neutrophils interspersed with nucleated red blood cells and some lymphocytes. The lymphocytes are irregular in size and shape with most of the cells being small mature lymphocytes. Atypical lymphoid cells or changes supporting sepsis cannot be identified.

PATIENT

Bluebell McGinley

INTERPRETATION OF THE FINDINGS & FURTHER RECOMMENDATIONS

Spleen - Mixed cell collection from the spleen with evidence of mild inflammation and lymphoid hyperplasia.

SPECIES

Feline

COMMENTS

The cellularity supports a chronic inflammatory process in the spleen. This could be secondary to inflammation in many locations in the abdominal cavity or within the systemic system of Bluebell. There are no changes in these collections to support neoplasia or sepsis. This suggests some type of chronic inflammation with evidence of regeneration of the red blood cells. If problems continue, further evaluation of other organs to identify a source for chronic inflammation may be beneficial. This could include chronic irritation of the intestine or even pancreatitis. A guarded prognosis is warranted until the underlying process can be identified.

BREED

DSH

SEX

FS

AGE

2years

WEIGHT

15#

HOSPITAL NAME

Rockaway Animal
Hospital

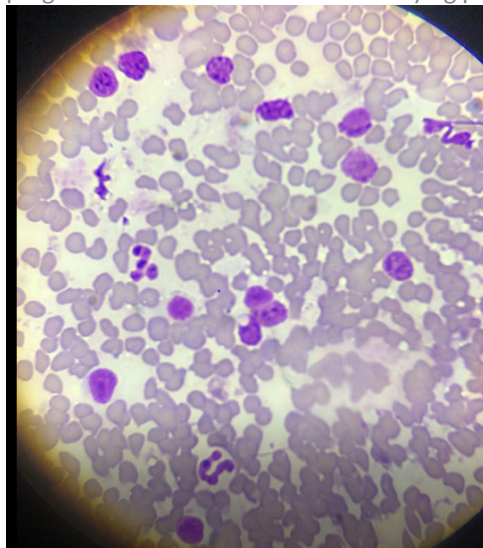


Image shows a mixture of cells collected from the spleen in Bluebell. Note the neutrophils with lymphocytes and a few NRBCs. There is no suggestion of malignancy or sepsis.

REFERRING VET

Dr. Maniar

The information and recommendations provided are based on the images presented by the referring veterinarian. No evaluation can be communicated regarding pathology that was not visible in the image/video clips provided.

INVOICE NUMBER

40504

Thank you for this referral. If the clinical or image interpretation does not parallel your findings or if I can be of any further assistance, please contact me.



DATE

4/18/22

L.D. McGill, DVM, Ph.D., DACVP
8288 Top of the World Drive
Cottonwood Heights, UT 84121
ldmcgill.vetpath@gmail.com
cell: 801-865-1220

INTERPRETED BY

L.D. McGill, DVM,
Ph.D., DACVP

PATIENT

Bluebell McGinley

SPECIES

Feline

BREED

DSH

SEX

FS

AGE

2years

WEIGHT

15#

HOSPITAL NAME

Rockaway Animal
Hospital

REFERRING VET

Dr. Maniar

INVOICE NUMBER

40504