



**DATE PRESENTING CLINICAL SIGNS**

4/17/23 Vomiting, diarrhea and not eating. Benedryl Inj before FNA of Spleen. Attempted FNA of pyloric wall lesion, but did not exfoliate well, minimally cellular slide. Ddx inflammatory vs neoplasia.

PE: BCS 4/9, QAR.

WBC 13.8k w/Neut 49%, Lymphs 32%, Mono 3%, Eos 15% (2k).

**INTERPRETED BY**

Rest of BW WNL.

AUS: thickened pyloric wall, loss of layering and hypoechoic. Mild splenomegaly. Reactive lymph node adjacent to pyloric lesion.

L.D. McGill, DVM,  
Ph.D, DACVP

**PATIENT CYTOLOGY SUBMISSION**

FNA of Spleen

Julia Naylor

**SPECIES OBSERVATIONS**

Feline

Spleen: Submitted are 7 excellent videos of very good collections of cells from the spleen in Julia. There is a mixed collection of nucleated cells. There is a background of red blood cells. The mixed collection of cells includes neutrophils, mature lymphocytes that are small, reactive red blood cells and scattered macrophages. There is minimal cellularity in many of the fields, but it is not atypical. There are no characteristics of malignancy in the collection.

**BREED**

DSH

**INTERPRETATION OF THE FINDINGS & FURTHER RECOMMENDATIONS**

SEX

Spleen - Chronic suppurative splenitis with no evidence of neoplasia

FS

**COMMENTS**

AGE

The cellularity supports a chronic inflammatory process including neutrophils draining to the spleen. The lymphoid cells are mature and reactive. There is no suggestion of neoplasia or suggestion of sepsis. Whenever this inflammatory process occurs, I'm always concerned about the potential of feline infectious peritonitis. Other types of chronic inflammatory processes should be considered. There could be neoplasia in the pyloric region and the spleen is only responding to secondary inflammation. A guarded prognosis is warranted since the underlying process is not identified.

WEIGHT

7 lbs

**HOSPITAL NAME**

Scanvet

**REFERRING VET**

Dr. McGarvey

**INVOICE NUMBER**

40709



**DATE**

4/17/23

**INTERPRETED BY**

L.D. McGill, DVM,  
Ph.D, DACVP

**PATIENT**

Julia Naylor

**SPECIES**

Feline

**BREED**

DSH

**SEX**

FS

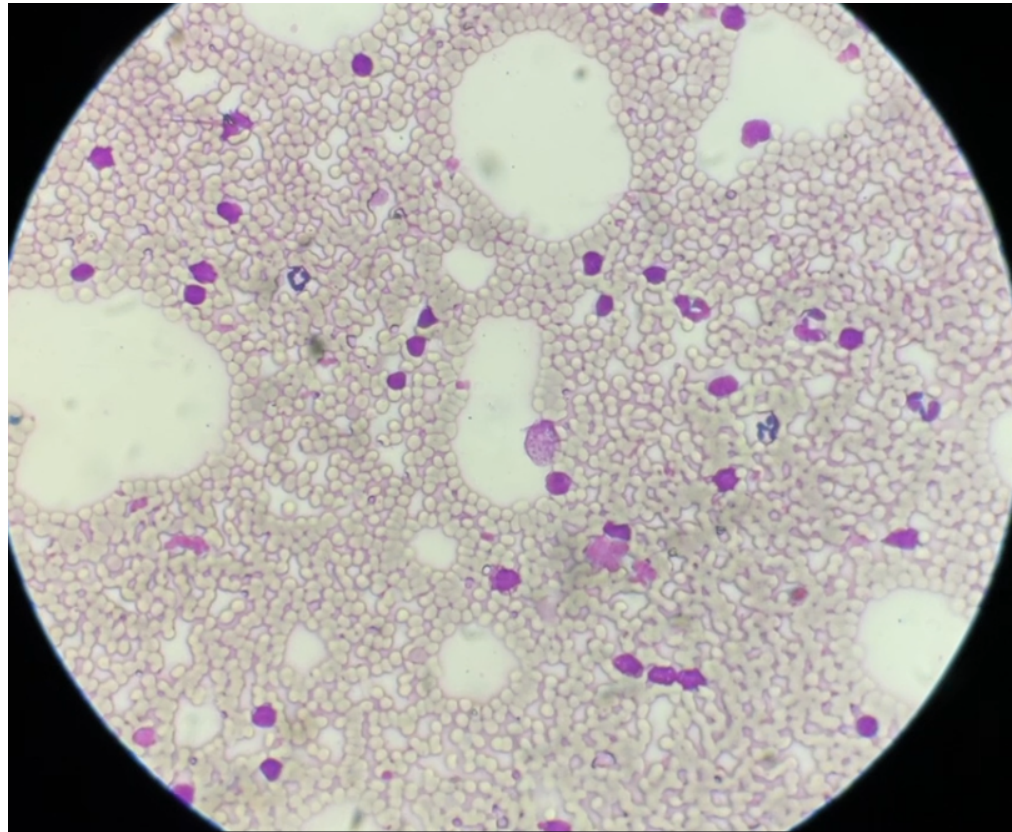


Image shows a mixed cell collection with neutrophils and mature lymphocytes from the spleen in Julia. There are no changes to suggest neoplasia.

**AGE**

6 years

The information and recommendations provided are based on the images presented by the referring veterinarian. No evaluation can be communicated regarding pathology that was not visible in the image/video clips provided.

**WEIGHT**

7 lbs

Thank you for this referral. If the clinical or image interpretation does not parallel your findings or if I can be of any further assistance, please contact me.

**HOSPITAL NAME**

Scanvet

L.D. McGill, DVM, Ph.D., DACVP  
8288 Top of the World Drive  
Cottonwood Heights, UT 84121  
ldmcgill.vetpath@gmail.com  
cell: 801-865-1220

**REFERRING VET**

Dr. McGarvey

**INVOICE NUMBER**

40709