



**DATE PRESENTING CLINICAL SIGNS**

4/15/23

Right ventrolat neck ~ quarter sized area of alopecia, raised pink, fleshy skin mass.

**CYTOLOGY SUBMISSION**

Skin lesion

**INTERPRETED BY**

L.D. McGill, DVM,  
Ph.D, DACVP

**OBSERVATIONS**

Skin lesion: Submitted are 4 very good videos of heavily stained cells collected from the skin lesion on Waylon. The first video consists of keratinized cells entirely. The other videos have good numbers of round cells that are occasionally packeted. Some of these cells have the appearance of lymphocytes and other cells have the appearance of macrophages and occasionally they are aggregated as if they are basaloid cells. There are scattered keratinized cells included in the smear.

**PATIENT**

Waylon Gallagher

**INTERPRETATION OF THE FINDINGS & FURTHER RECOMMENDATIONS**

Skin lesion - Keratinized cells with lymphocytes and some cells suggesting basaloid cells.

**SPECIES COMMENTS**

Canine

If this is a superficial skin collection, then it is keratinized with lymphocytes and some basaloid cells which could be any type of localized chronic inflammatory process. I am suspecting that this is a fine needle aspirate with keratinized cells and basaloid cells. This appears to be a keratinized cystic process such as an epidermal inclusion cyst or follicular cyst with chronic inflammation. Cytologically it is benign. There is some inflammation. Excision of the mass is encouraged after evaluating these cytologic collections. Your understanding of how this sample was collected will confirm the underlying process.

**BREED**

Retriever

**SEX**

Male Neutered

**AGE**

6y

**WEIGHT**

78.5 lbs

**HOSPITAL NAME**

Central Veterinary  
Hospital

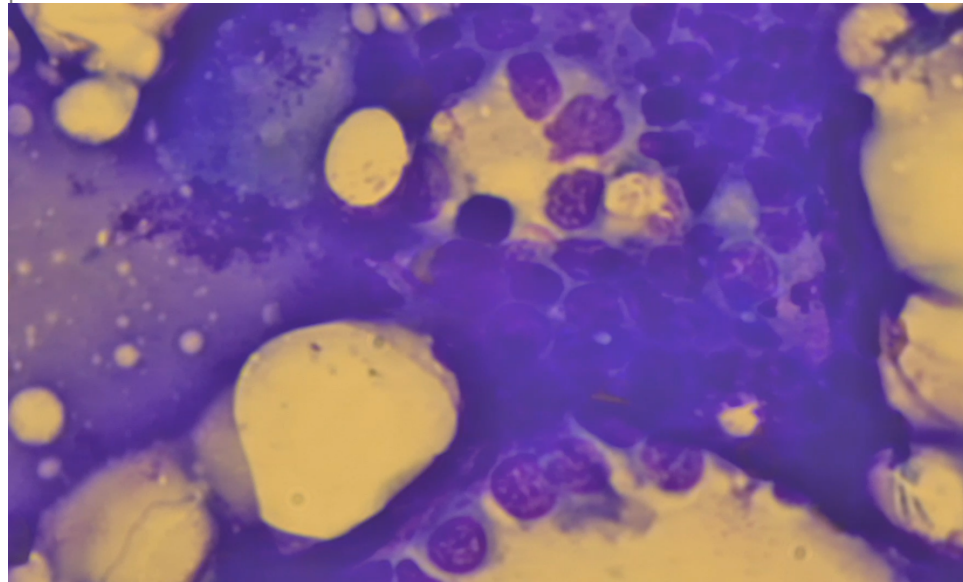


Image shows a group of round cells with a keratinized cell in the upper left collected from the skin lesion on Waylon. The round cells may be lymphocytes but I am interpreting them as basaloid cells in this image.

**REFERRING VET**

Dr. Goeldner

The information and recommendations provided are based on the images presented by the referring veterinarian. No evaluation can be communicated regarding pathology that was not visible in the image/video clips provided.

**INVOICE NUMBER**

931



**DATE** 4/15/23 Thank you for this referral. If the clinical or image interpretation does not parallel your findings or if I can be of any further assistance please contact me.

**INTERPRETED BY** L.D. McGill, DVM, Ph.D., DACVP  
8288 Top of the World Drive  
Cottonwood Heights, UT 84121  
ldmcgill.vetpath@gmail.com  
cell: 801-865-1220

**PATIENT**  
Waylon Gallagher

**SPECIES**  
Canine

**BREED**  
Retriever

**SEX**  
Male Neutered

**AGE**  
6y

**WEIGHT**  
78.5 lbs

**HOSPITAL NAME**  
Central Veterinary  
Hospital

**REFERRING VET**  
Dr. Goeldner

**INVOICE NUMBER**  
931