



DATE PRESENTING CLINICAL SIGNS

4/15/23

Right Caudal mammary gland mass was detected on PE which involved caudal two mammary glands

INTERPRETED BY

L.D. McGill, DVM,
Ph.D, DACVP

Hypercalcemia and azotemia was noticed. On ultrasound examination, one highly enlarged heterogenous iliac lymph node was seen. Another moderately enlarged heterogenous iliac lymph node was also noticed. Metastasis is suspected in this case. FNA of the mammary gland was done and it was submitted for examination

CYTOLOGY SUBMISSION

Mammary region

PATIENT

Arya Mansour

OBSERVATIONS

Mammary region: Submitted is 1 very good video of good collections of cells from the mass aspirated from the mammary region on Arya. The cellularity consists almost entirely of round cells. There are good numbers of macrophages with foamy cytoplasm. Interspersed are prominent lymphocytes. There are even a couple of cells that may be plasma cells. I did not identify characteristics of malignancy. The changes are most consistent with chronic inflammation.

SPECIES

Canine

INTERPRETATION OF THE FINDINGS & FURTHER RECOMMENDATIONS

Mammary region - Chronic granulomatous inflammation

BREED

Saluki cross

COMMENTS

The cellularity supports chronic inflammation and not malignancy. This chronic inflammation could be the result of a primary inflammatory process locally or it could be the result of inflammation within a neoplastic process. If it is within a neoplastic process, then those cells are not sloughing into this collection. With the internal lymph node swelling, I'm concerned about a chronic inflammatory process that is draining to those nodes. This could be chronic mastitis or could be due to other inflammatory processes. Again, I was unable to identify any evidence of neoplasia in this collection of cells. However, neoplasia cannot be ruled out. A guarded prognosis is warranted since the underlying process has not been identified.

SEX

Female intact

AGE

8y

WEIGHT

21

HOSPITAL NAME

City Veterinary Clinic,
Abu Dhabi

REFERRING VET

Dr. Inam ul haq

INVOICE NUMBER

930



DATE

4/15/23

INTERPRETED BY

L.D. McGill, DVM,
Ph.D, DACVP

PATIENT

Arya Mansour

SPECIES

Canine

BREED

Saluki cross

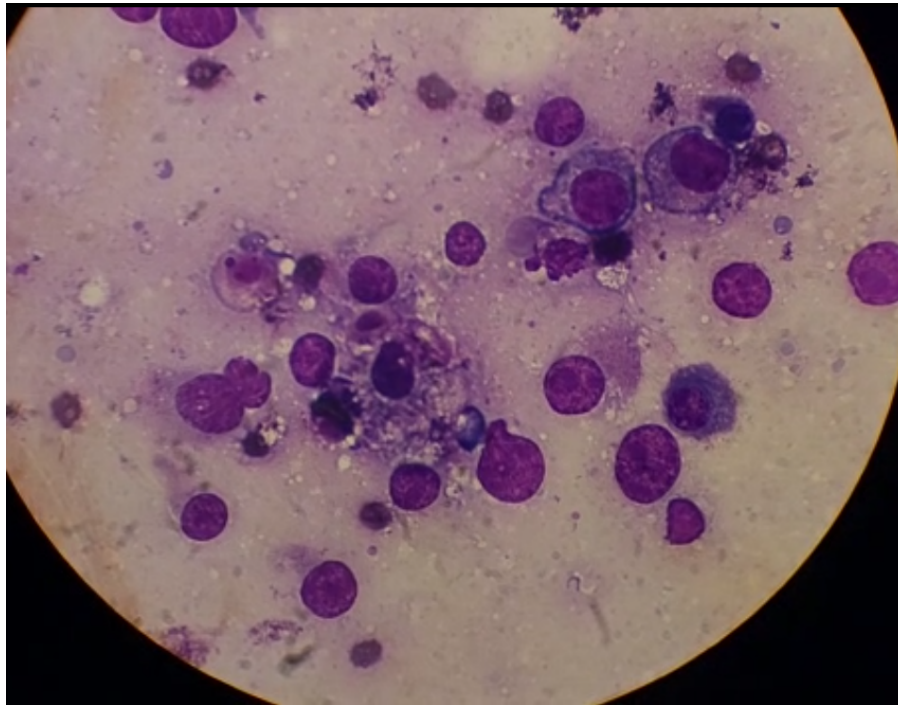


Image shows a representative collection of round cells collected from Arya. There are several macrophages in the field and one has a foamy cytoplasm. Most of the other cells suggest lymphocytes.

SEX

Female intact

AGE

8y

The information and recommendations provided are based on the images presented by the referring veterinarian. No evaluation can be communicated regarding pathology that was not visible in the image/video clips provided.

Thank you for this referral. If the clinical or image interpretation does not parallel your findings or if I can be of any further assistance please contact me.

WEIGHT

21

L.D. McGill, DVM, Ph.D., DACVP
8288 Top of the World Drive
Cottonwood Heights, UT 84121
ldmcgill.vetpath@gmail.com
cell: 801-865-1220

HOSPITAL NAME

City Veterinary Clinic,
Abu Dhabi

REFERRING VET

Dr. Inam ul haq

INVOICE NUMBER

930