



DATE **PRESENTING CLINICAL SIGNS**
4/15/22 Previously scanned on 4/5 for weight loss and elevated liver values.
Large abdominal mass found.

INTERPRETED BY **CYTOLOGY SUBMISSION**
L.D. McGill, DVM, Ph.D, DACVP Liver mass

PATIENT **OBSERVATIONS**
Casey Steffen Liver mass: Submitted are 6 excellent videos of excellent collections of cells from the liver mass in the abdominal cavity in Casey. Almost all of the fields have aggregates of hepatocytes of irregular size and shape. Most of the hepatocytes are small. There is slight anisokaryosis. There are scattered individualized cells that appear to be hepatocytes as well. There is minimal inflammation in the surrounding red blood cell collection. The hepatocytes are not markedly atypical but they are definitely irregular to small size.

SPECIES **INTERPRETATION OF THE FINDINGS & FURTHER RECOMMENDATIONS**
Canine Liver mass - Consistent with hepatocellular adenoma or possible extrahepatic liver tissue.

BREED **COMMENTS**
Rottweiler Mix The cellularity throughout all of these videos is characteristic of hepatocellular tissue. A hepatocellular adenoma can be considered or this could be an accessory liver lobe of some type. In my opinion it is not showing characteristics of aggressive malignancy. If Casey is up for surgery, it would be my opinion that this lesion could be excised with the description you have given. If the mass can be completely excised, then a favorable prognosis is likely since there appears to be a low-grade or benign appearance to these cells.

SEX
Male Neutered

AGE
13y

WEIGHT
36.5kg

HOSPITAL NAME
Silver Creek Animal Clinic

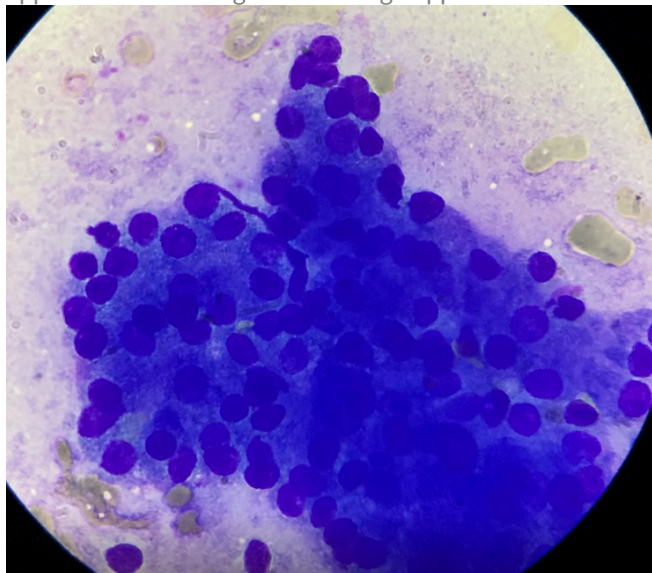


Image shows a group of small hepatocytes collected from the abdominal mass in Casey. Note the mild anisokaryosis and small size of the hepatocytes.

REFERRING VET

Dr. Tangeman

The information and recommendations provided are based on the images presented by the referring veterinarian. No evaluation can be communicated regarding pathology that was not visible in the image/video clips provided.

INVOICE NUMBER

715



DATE Thank you for this referral. If the clinical or image interpretation does not parallel your findings or if I can be of any further assistance please contact me.
4/15/22

INTERPRETED BY L.D. McGill, DVM, Ph.D., DACVP
8288 Top of the World Drive
Cottonwood Heights, UT 84121
ldmcgill.vetpath@gmail.com
cell: 801-865-1220

PATIENT
Casey Steffen

SPECIES
Canine

BREED
Rottweiler Mix

SEX
Male Neutered

AGE
13y

WEIGHT
36.5kg

HOSPITAL NAME
Silver Creek Animal
Clinic

REFERRING VET
Dr. Tangeman

INVOICE NUMBER
715