



DATE **PRESENTING CLINICAL SIGNS**
4/14/23 Generalized Peripheral Lymphadenopathy
FNA from Popliteal LN's

INTERPRETED BY **CYTOLOGY SUBMISSION**
Lymph Node

L.D. McGill, DVM,
Ph.D, DACVP

OBSERVATIONS

Lymph node: Submitted are 5 excellent videos of irregularly stained cells collected from the lymph node on Opie. The cellularity consists almost entirely of lymphoid cells, many of which appear to be large cells. They have nuclei that are 2 to 4 times the size of red blood cells. Nucleoli are varied in size and numbers in the nuclei of these cells. Where cytoplasm can be identified, it is narrow with bluish gray appearance. There were scattered neutrophils in the collection. The large cells are 60 to 70% of the lymphoid cells in the collection. There were some small cells present.

PATIENT

Opie McFeaters

INTERPRETATION OF THE FINDINGS & FURTHER RECOMMENDATIONS

SPECIES Lymph node - Suggestive of high-grade lymphoma.

Canine

COMMENTS

The cellularity in these videos is irregularly stained where it is really light, the cells are difficult to interpret. Other areas demonstrate well stained cells that strongly suggest the possibility of a high-grade lymphoma. The nucleoli are prominent and the large nuclei are suspicious. Further evaluation to confirm lymphoma is encouraged. If chemotherapy is contemplated, then immunophenotyping of the cells to confirm the specific cell type may be beneficial for prognosis. The slides may be submitted for PARR testing or new slides that are not stained can be submitted for immunocytochemistry staining. Flow cytometry can be beneficial but will require a repeat collection of cells prior to submission to the laboratory. Contacting the laboratory to confirm how to submit flow cytometry samples is encouraged. A guarded to unfavorable prognosis is warranted in my opinion

BREED

Pitbull

SEX

Male

AGE

6y

WEIGHT

50 lbs

HOSPITAL NAME

Franklin Veterinary
Clinic

REFERRING VET

Dr. Doverspike

INVOICE NUMBER

929

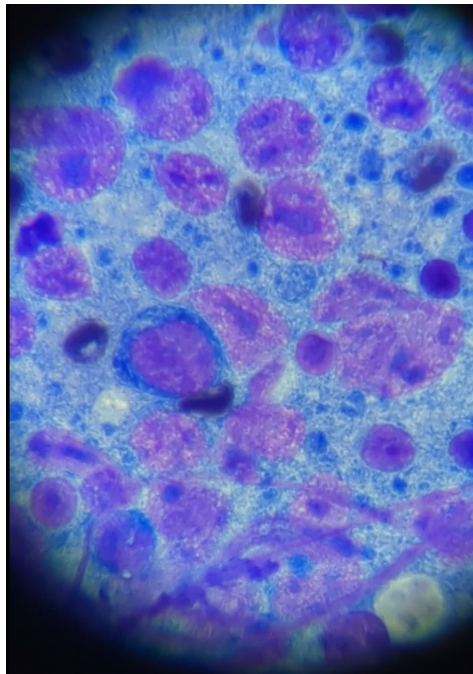


Image shows a field of lymphocytes collected from the lymph node on Opie. Note the large cells as compared to the small lymphocyte in the upper right edge. Nucleoli are prominent.



DATE 4/14/23 The information and recommendations provided are based on the images presented by the referring veterinarian. No evaluation can be communicated regarding pathology that was not visible in the image/video clips provided.

INTERPRETED BY L.D. McGill, DVM, Ph.D., DACVP Thank you for this referral. If the clinical or image interpretation does not parallel your findings or if I can be of any further assistance please contact me.

L.D. McGill, DVM,
Ph.D., DACVP

L.D. McGill, DVM, Ph.D., DACVP
8288 Top of the World Drive
Cottonwood Heights, UT 84121
ldmcgill.vetpath@gmail.com
cell: 801-865-1220

PATIENT
Opie McFeaters

SPECIES

Canine

BREED

Pitbull

SEX

Male

AGE

6y

WEIGHT

50 lbs

HOSPITAL NAME

Franklin Veterinary
Clinic

REFERRING VET

Dr. Doverspike

INVOICE NUMBER

929