



DATE PRESENTING CLINICAL SIGNS

4/14/22

FNA: Intestinal mass

CYTOLOGY SUBMISSION

FNA of Intestinal mass

INTERPRETED BY

L.D. McGill, DVM,
Ph.D, DACVP

OBSERVATIONS

Intestinal mass: Submitted are 5 excellent videos of excellent collections of cells from the intestinal mass in Nico. The cellularity is mixed in many of the videos but there are quite prominent round cells in others. The round cells are large lymphoid cells with prominent nucleoli. In other fields there are mixtures of macrophages interspersed with neutrophils and lymphoid cells. Irregular large atypical lymphoid cells are identified in most fields.

PATIENT

Nico Warshauer

INTERPRETATION OF THE FINDINGS & FURTHER RECOMMENDATIONS

Intestinal mass - Consistent with high grade lymphoma with secondary pyogranulomatous inflammation.

SPECIES

Feline

COMMENTS

In many of the videos, the cellularity is mixed causing some difficulty in interpretation. However, in at least two of the videos the cellularity is almost all large atypical lymphoid cells. These cells have nuclei that are extremely large with minimal cytoplasm. Some of the cells are vacuolated. There is some research suggesting that excision of these lesions will prolong the life of the affected cat. This can be attempted. Further evaluation by immunophenotyping can be undertaken but in my experience, this is not as helpful for prognosis in the cat as in the dog. An unfavorable prognosis is warranted in my opinion due to the large number of atypical lymphoid cells.

BREED

DSH

SEX

Male Neutered

AGE

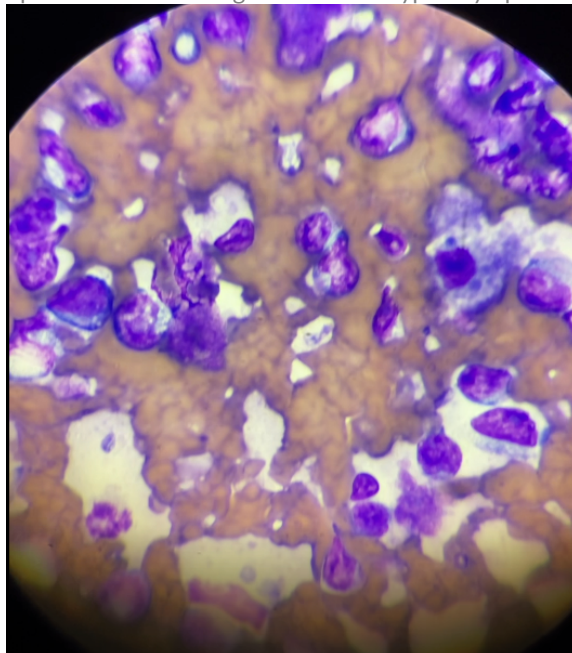
10yr

WEIGHT

10#

HOSPITAL NAME

Newton Veterinary
Hospital



REFERRING VET

Dr. Wyman-Greenwald

Image shows a field with many large irregular lymphoid cells and scattered macrophages collected from the intestine in Nico. Note the prominent nucleoli in the large lymphoid cells.

The information and recommendations provided are based on the images presented by the referring veterinarian. No evaluation can be communicated regarding pathology that was not visible in the image/video clips provided.

INVOICE NUMBER

40502



DATE

4/14/22

Thank you for this referral. If the clinical or image interpretation does not parallel your findings or if I can be of any further assistance, please contact me.

INTERPRETED BY

L.D. McGill, DVM,
Ph.D, DACVP

L.D. McGill, DVM, Ph.D., DACVP

8288 Top of the World Drive
Cottonwood Heights, UT 84121
ldmcgill.vetpath@gmail.com
cell: 801-865-1220

PATIENT

Nico Warshauer

SPECIES

Feline

BREED

DSH

SEX

Male Neutered

AGE

10yr

WEIGHT

10#

HOSPITAL NAME

Newton Veterinary
Hospital

REFERRING VET

Dr. Wyman-Greenwald

INVOICE NUMBER

40502