



DATE **PRESENTING CLINICAL SIGNS**
4/14/22 presented with prominent firm popliteal lymph nodes, last vaccines were given in left shoulder, and rabies right hind on 4/2/22

INTERPRETED BY **CYTOLOGY SUBMISSION**
L.D. McGill, DVM, Ph.D, DACVP FNA of Lymph Node

PATIENT **OBSERVATIONS**
Crisp AC PAW Lymph node aspirate: Submitted are 10 images collected from the left popliteal lymph node and 11 images collected from the right popliteal lymph node on Crisp. The cellularity on the images from both sides includes large numbers of small mature lymphocytes. They are interspersed with irregular large reactive lymphoid cells. Atypical cells are not readily identified. Some of the cells are smudged. There are scattered plasma cells and scattered intermediate lymphoid cells.

SPECIES **INTERPRETATION OF THE FINDINGS & FURTHER RECOMMENDATIONS**
Feline Lymph node aspirate - Bilateral reactive or stimulated lymphoid tissue.

BREED **COMMENTS**
DSH The cellularity in this collection from both lymph nodes suggests some type of lymphoid stimulation. This very easily could be from the immunization and an antigenic response systemically. I am unable to identify malignant characteristics in the cells in this collection. Continued monitoring is encouraged. I suspect that the lymph nodes will decrease in size in the near future. This could also be the result of reactive lymphoid tissue in young. This is a benign process that has been described. It usually occurs in cats four years or younger. At this time, I expect a favorable prognosis in Crisp.

SEX
Male Neutered

AGE
3y

WEIGHT
8.3

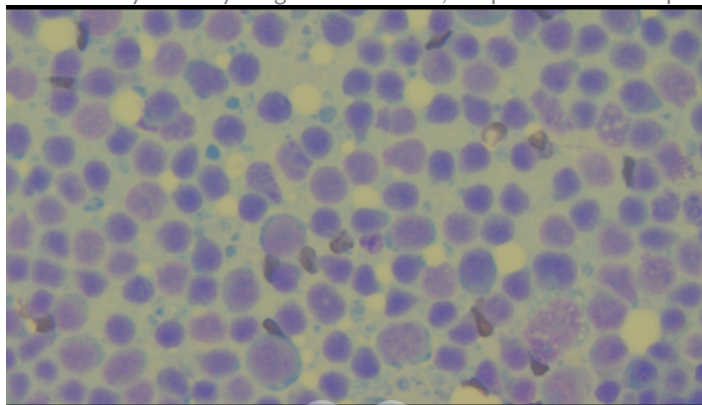


Image shows a representative cellularity collected from the lymph nodes in Crisp. There are scattered reactive lymphocytes, but the majority are small to intermediate lymphocytes and mixed in size.

HOSPITAL NAME **The information and recommendations provided are based on the images presented by the referring veterinarian. No evaluation can be communicated regarding pathology that was not visible in the image/video clips provided.**
Torch Lake Veterinary Clinic

Thank you for this referral. If the clinical or image interpretation does not parallel your findings or if I can be of any further assistance, please contact me.

REFERRING VET
Dr. Adrienne Waffle
L.D. McGill, DVM, Ph.D., DACVP
8288 Top of the World Drive
Cottonwood Heights, UT 84121
ldmcgill.vetpath@gmail.com
cell: 801-865-1220

INVOICE NUMBER
40503



DATE

4/14/22

INTERPRETED BY

L.D. McGill, DVM,
Ph.D, DACVP

PATIENT

Crisp AC PAW

SPECIES

Feline

BREED

DSH

SEX

Male Neutered

AGE

3y

WEIGHT

8.3

HOSPITAL NAME

Torch Lake Veterinary
Clinic

REFERRING VET

Dr. Adrienne Waffle

INVOICE NUMBER

40503