



DATE	PRESENTING CLINICAL SIGNS
4/13/23	ADR, Weight Loss, Poor Appetite. PU/PD WBC 70.10 K/ μ L 5.05 - 16.76 HIGH %NEU * 74.7 % %LYM * 10.7 %
INTERPRETED BY	%MONO * 10.3 % %EOS * 4.2 % %BASO 0.1 % NEU * 52.43 K/ μ L 2.95 - 11.64 HIGH BAND * Suspected LYM * 7.47 K/ μ L 1.05 - 5.10 HIGH MONO * 7.21 K/ μ L 0.16 - 1.12 HIGH EOS * 2.94 K/ μ L 0.06 - 1.23 HIGH BASO 0.05 K/ μ L 0.00 - 0.10 PLT * 144 K/ μ L 148 - 484 LOW
L.D. McGill, DVM, Ph.D, DACVP	
PATIENT	SPECIES
Odie Gill	Abdominal U/S (My Interpretatin) Shows an enlarged spleen with changes in the parenchyma suggestive of a round cell neoplasia. The liver looks infiltrative and there is a small amount of free fluid in the abdomen.
	Canine
BREED	CYTOLOGY SUBMISSION
Bulldog X	FNA of Spleen
SEX	OBSERVATIONS
Male Neutered	Spleen: Submitted are 6 excellent videos of cells collected from the spleen in Odie. There are large fields of neutrophils interspersed with reactive macrophages with foamy cytoplasm and scattered lymphocytes and nucleated red blood cells. There are scattered eosinophils and basophils. Mast cells were not identified. The background granularity consists of inspissated protein or stain pigment. There are no characteristics of malignancy in the collection.
AGE	INTERPRETATION OF THE FINDINGS & FURTHER RECOMMENDATIONS
6 years	Spleen - Severe chronic suppurative and suggested pyogranulomatous splenitis with reactive cells.
WEIGHT	COMMENTS
72	The cellularity is characteristic of a rather severe splenitis which is likely centered in some other location in the body. There were several macrophages that included neutrophils in the cytoplasm. This is possibly an immune mediated process or severe bacterial infection. There is no suggestion of malignancy, but sepsis is possible. The granular material in the background is nonspecific. There are no mast cells that I could identify in this is excellently stained and collected cellularity. Specific etiologic agents are not identified. A guarded prognosis is warranted since there is a marked neutrophilic cellularity throughout this collection.
HOSPITAL NAME	
Franklin Animal Clinic Inc.	
REFERRING VET	
Dr. Doverspike	
INVOICE NUMBER	
40707	



DATE

4/13/23

INTERPRETED BY

L.D. McGill, DVM,
Ph.D, DACVP

PATIENT

Odie Gill

SPECIES

Canine

BREED

Bulldog X

SEX

Male Neutered

AGE

6 years

WEIGHT

72

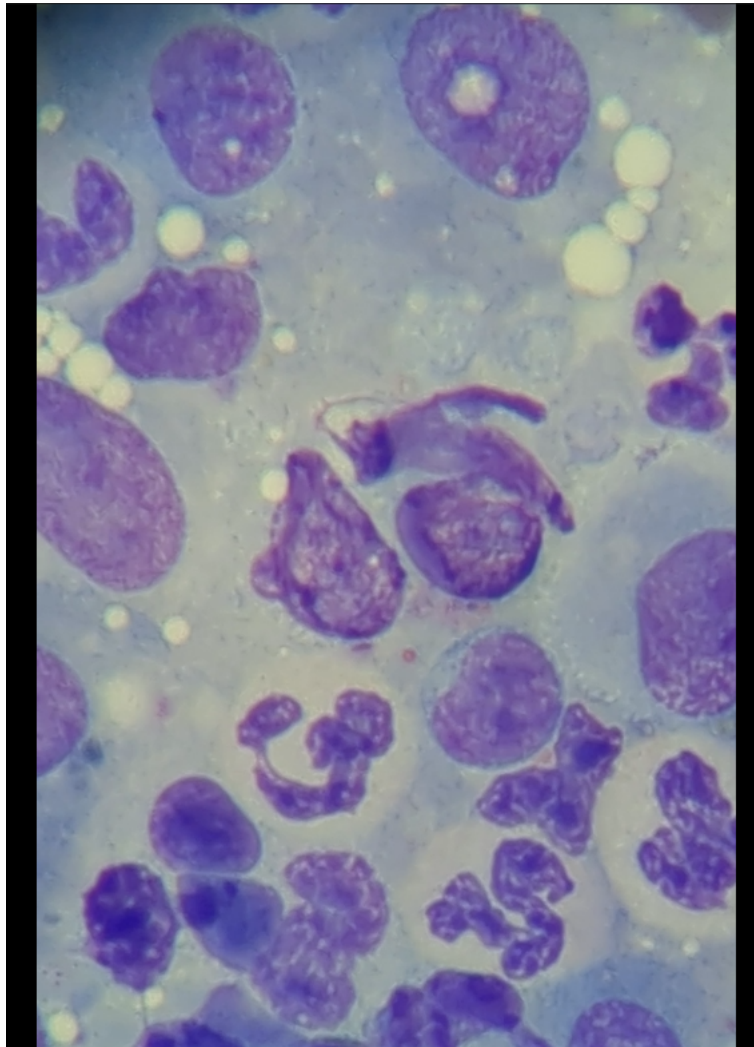


Image shows a group of cells collected from the spleen in Odie. Neutrophils are prominent with lymphocytes and macrophages in this field. There are no malignant characteristics.

HOSPITAL NAME

Franklin Animal Clinic
Inc.

The information and recommendations provided are based on the images presented by the referring veterinarian. No evaluation can be communicated regarding pathology that was not visible in the image/video clips provided.

Thank you for this referral. If the clinical or image interpretation does not parallel your findings or if I can be of any further assistance, please contact me.

REFERRING VET

Dr. Doverspike

L.D. McGill, DVM, Ph.D., DACVP
8288 Top of the World Drive
Cottonwood Heights, UT 84121
ldmcgill.vetpath@gmail.com
cell: 801-865-1220

INVOICE NUMBER

40707



DATE

4/13/23

INTERPRETED BY

L.D. McGill, DVM,
Ph.D, DACVP

PATIENT

Odie Gill

SPECIES

Canine

BREED

Bulldog X

SEX

Male Neutered

AGE

6 years

WEIGHT

72

HOSPITAL NAME

Franklin Animal Clinic
Inc.

REFERRING VET

Dr. Doverspike

INVOICE NUMBER

40707