



**DATE PRESENTING CLINICAL SIGNS**

4/13/22

Patient presented for exam on 4/13/22. A small, 4mm, raised, hairless, pink cutaneous mass was noted on the left cranial stifle. The mass has a known duration of ~1 month. Attached videos show sample collected from mass via FNA.

**INTERPRETED BY CYTOLOGY SUBMISSION**

L.D. McGill, DVM,  
Ph.D, DACVP

FNA of Dermal

**PATIENT**

Rico Caggiano

**OBSERVATIONS**

Skin lesion: Submitted are 3 excellent videos of minimal to moderate cellular collections from the skin mass on Rico. The cellularity is rather consistent throughout all the videos. The nuclei are rounded with minimal evidence of nucleoli. The cytoplasm is prominent and elongated to rounded. Occasional binucleate cells are identified. There are scattered cells that appear to have a halo on one side of the nucleus. Many of the cells demonstrate irregular vacuoles.

**INTERPRETATION OF THE FINDINGS & FURTHER RECOMMENDATIONS**

**SPECIES**

Canine

Skin lesion - Consistent with round cell tumor such as a plasmacytoma, possible histiocytoma or histiocytic synovial sarcoma.

**BREED**

Chihuahua

**COMMENTS**

With the binucleate cells and the halo on one edge of the nucleus in some of the cells, I am suspicious of a plasmacytoma. It could also be a histiocytoma in an older dog. They seem to become more common in older dogs and younger dogs. This is probably due to immunologic problems in older dogs. If the mass is connected to the joint, then a histiocytic synovial sarcoma can be considered as a diagnosis. Excision of the mass with a follow-up biopsy is encouraged. This should assist in confirming the diagnosis. The cells do not have an overt aggressive pattern of neoplasia. I expect a favorable prognosis with excision.

**SEX**

Male Neutered

**AGE**

13y

**WEIGHT**

9#

**HOSPITAL NAME**

Rotterdam Veterinary  
Hospital

**REFERRING VET**

Dr. Anna St Sir

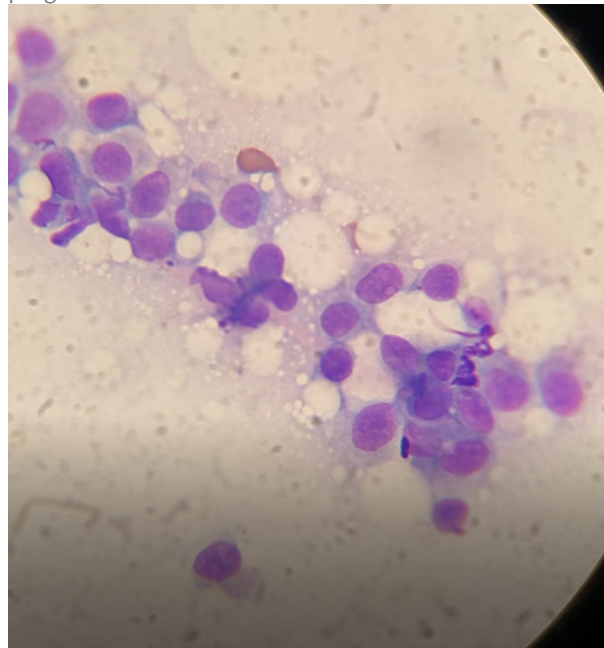


Image shows a group of round cells collected from the skin mass on Rico. There are irregular vacuoles in many cells. Note the anisokaryosis.

**INVOICE NUMBER**

40500



**DATE**

4/13/22

**INTERPRETED BY**

L.D. McGill, DVM,  
Ph.D., DACVP

The information and recommendations provided are based on the images presented by the referring veterinarian. No evaluation can be communicated regarding pathology that was not visible in the image/video clips provided.

Thank you for this referral. If the clinical or image interpretation does not parallel your findings or if I can be of any further assistance, please contact me.

**PATIENT**

Rico Caggiano

**L.D. McGill, DVM, Ph.D., DACVP**  
8288 Top of the World Drive  
Cottonwood Heights, UT 84121  
ldmcgill.vetpath@gmail.com  
cell: 801-865-1220

**SPECIES**

Canine

**BREED**

Chihuahua

**SEX**

Male Neutered

**AGE**

13y

**WEIGHT**

9#

**HOSPITAL NAME**

Rotterdam Veterinary  
Hospital

**REFERRING VET**

Dr. Anna St Sir

**INVOICE NUMBER**

40500