



**DATE PRESENTING CLINICAL SIGNS**

4/12/23

Presented for acute vomiting and soft stools 4/10, owner adopted about a month ago so a new dog to the owner with unknown history.  
PE: Caudal abdominal mass (firm, by the bladder).  
Senior wellness panel pending.

**INTERPRETED BY**

L.D. McGill, DVM,  
Ph.D, DACVP

RADS: circular soft tissue density in caudal abdomen.  
AUS: apx. 5 cm x 4 cm x 4 cm irregular cystic/soft tissue structure just cranial to bladder, and adjacent to, but separate from colon. Rest of abdomen is WNL.

**PATIENT CYTOLOGY SUBMISSION**

Poppy Williams

FNA done of abnormal cystic/soft tissue area cranial to bladder.

**OBSERVATIONS**

**SPECIES**

Canine

Caudal abdominal mass: Submitted are 6 excellent videos of minimal nucleated cellular collections from the caudal abdominal mass in Poppy. There are very few nucleated cells but there are prominent red blood cells and there appears to be fluid. The nucleated cellularity is mixed including neutrophils with some lymphocytes and a clump of reactive mesothelial cells. There is no suggestion of malignancy or sepsis.

**BREED**

Shih tzu mix

**INTERPRETATION OF THE FINDINGS & FURTHER RECOMMENDATIONS**

Caudal abdominal mass - Consistent with a seroma with hemorrhage and mild inflammation.

**SEX**

FS

**COMMENTS**

The cellularity is most characteristic of a localized area of fluid collection with hemorrhage and inflammation. There is no suggestion of malignancy or sepsis. I suspect that this is a secondary change from the spay surgery, but it could be secondary to many different conditions. Continued monitoring for problems with some of the surrounding organs including the potential of a seroma or hematoma in the region is encouraged. I did not identify adequate cells to support a granuloma or neoplasia. A guarded prognosis is warranted since the underlying process is not identified.

**AGE**

Apx. 8 years

**WEIGHT**

13.2 lbs

**HOSPITAL NAME**

Scanvet

**REFERRING VET**

Dr. Cohen

**INVOICE NUMBER**

40705



**DATE**

4/12/23

**INTERPRETED BY**

L.D. McGill, DVM,  
Ph.D., DACVP

**PATIENT**

Poppy Williams

**SPECIES**

Canine

**BREED**

Shih tzu mix

**SEX**

FS

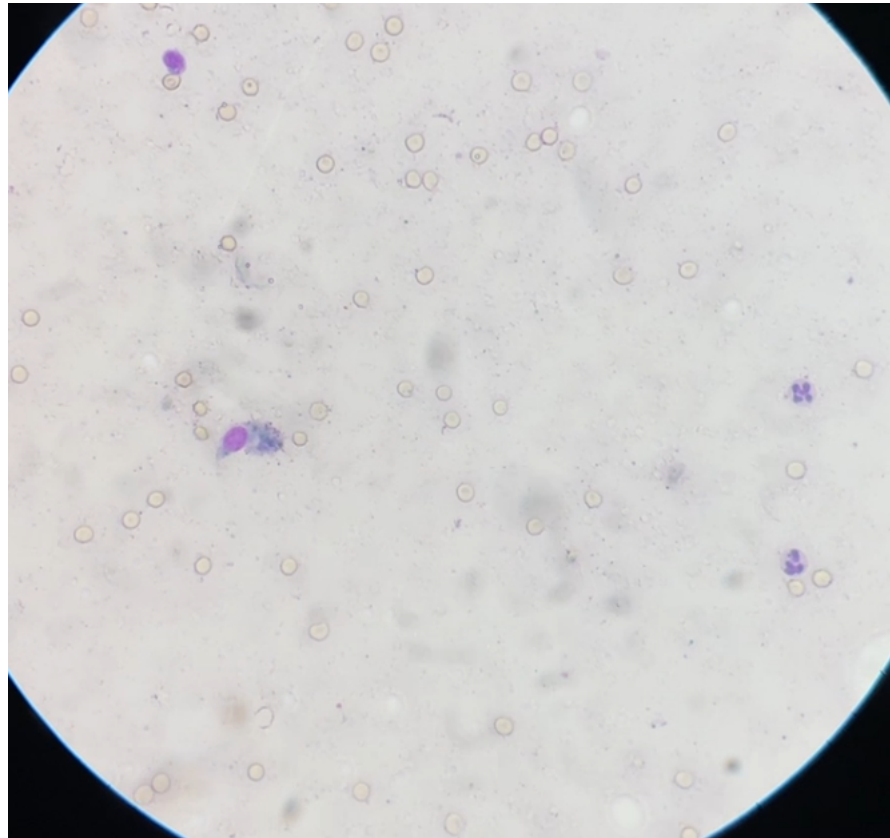


Image shows RBCs with a mixture of inflammatory cells including neutrophils collected from the aspirate in Poppy. Note the paucity of nucleated cells.

**AGE**

Apx. 8 years

The information and recommendations provided are based on the images presented by the referring veterinarian. No evaluation can be communicated regarding pathology that was not visible in the image/video clips provided.

**WEIGHT**

13.2 lbs

Thank you for this referral. If the clinical or image interpretation does not parallel your findings or if I can be of any further assistance, please contact me.

**HOSPITAL NAME**

Scanvet

L.D. McGill, DVM, Ph.D., DACVP  
8288 Top of the World Drive  
Cottonwood Heights, UT 84121  
ldmcgill.vetpath@gmail.com  
cell: 801-865-1220

**REFERRING VET**

Dr. Cohen

**INVOICE NUMBER**

40705