



**DATE PRESENTING CLINICAL SIGNS**

4/12/22

Patient presented for vomiting in March of 2022. Enlarged mesenteric lymph node noted on abdominal ultrasound. Patient presented now (4/12/22) with bloody diarrhea, elevated WBC, elevated lymph. Submandibular, prescapular and popliteal lymph nodes enlarged on exam. Sample attached is take from submandibular lymph node.

**INTERPRETED BY**

L.D. McGill, DVM,  
Ph.D, DACVP

**CYTOLOGY SUBMISSION**

Lymph node

**OBSERVATIONS**

Lymph node: Submitted are 3 excellent videos of material collected from the lymph node in Jasmine. The majority of the smears consist of smudged and degenerate cellularity. These smudged cells are likely lymphocytes but they are uninterpretable. There are scattered small mature lymphocytes and very rare intermediate lymphocytes identified.

**PATIENT**

Jasmine Kami

**INTERPRETATION OF THE FINDINGS & FURTHER RECOMMENDATIONS**

**SPECIES** Lymph node - Smudged, degenerate cells (probable lymphocytes) with scattered small mature lymphocytes.

Canine

**COMMENTS**

The collection in this submission is very likely from the lymph node but the cells are extremely smudged. This may be due to rough smearing of the cells or could be due to necrosis in the lymph node. I am unable to determine which of those is the major process. There are many cells that are smudged due to smearing of these cells. The lymphoid cells could be extremely fragile. There are no characteristics of malignancy or sepsis but there could be inflammation associated with the lymph nodes. Recollection or biopsy would be encouraged. Continued evaluation for systemic inflammatory processes including tick borne infectious diseases is encouraged.

**BREED**

Beagle

**SEX**

Female Spayed

**AGE**

10y

**WEIGHT**

35#

**HOSPITAL NAME**

Rotterdam Veterinary  
Hospital

**REFERRING VET**

Dr. St Sir

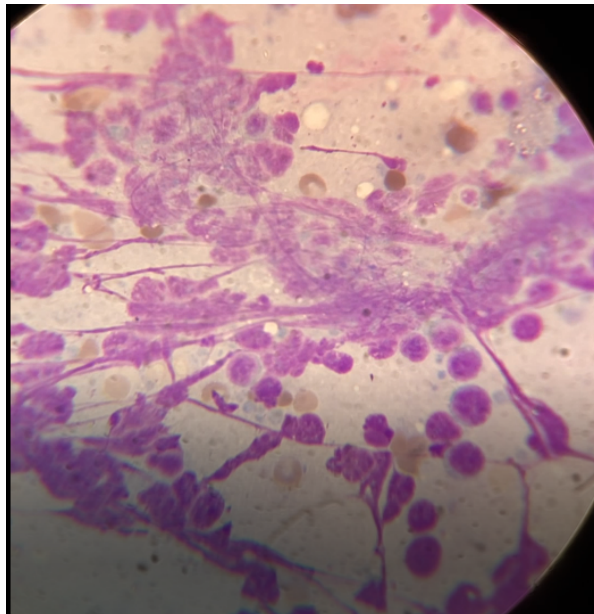


Image shows a large number of smudge cells with some small to intermediate sized lymphocytes. This is a representative field in the videos.

**INVOICE NUMBER**

714



**DATE**

4/12/22

The information and recommendations provided are based on the images presented by the referring veterinarian. No evaluation can be communicated regarding pathology that was not visible in the image/video clips provided.

**INTERPRETED BY**

L.D. McGill, DVM,  
Ph.D., DACVP

Thank you for this referral. If the clinical or image interpretation does not parallel your findings or if I can be of any further assistance please contact me.

**PATIENT**

Jasmine Kami

**L.D. McGill, DVM, Ph.D., DACVP**  
8288 Top of the World Drive  
Cottonwood Heights, UT 84121  
ldmcgill.vetpath@gmail.com  
cell: 801-865-1220

**SPECIES**

Canine

**BREED**

Beagle

**SEX**

Female Spayed

**AGE**

10y

**WEIGHT**

35#

**HOSPITAL NAME**

Rotterdam Veterinary  
Hospital

**REFERRING VET**

Dr. St Sir

**INVOICE NUMBER**

714