



**DATE PRESENTING CLINICAL SIGNS**

4/12/23

Progressive elevation of ALT and ALP. Polyphagic, waxing and waning diarrhea, mild PU/PD.  
Current meds: just D/C Rimadyl (was on for OA)  
ALT 254, ALP 1179, Cholesterol 380

**INTERPRETED BY**

L.D. McGill, DVM,  
Ph.D, DACVP

**CYTOLOGY SUBMISSION**

FNA of Liver

**PATIENT**

Maggie Hewitt

**SPECIES**

Canine

**BREED**

Vizsla

**SEX**

FS

**AGE**

13yrs

**WEIGHT**

62#

**OBSERVATIONS**

Liver: Submitted are 12 excellent videos of cells collected from the liver in Maggie. There are good collections of hepatocytes demonstrating vacuolization and granularity of the cytoplasm. Interspersed in the surrounding red blood cells are a mixture of inflammatory cells. Lymphocytes are readily identified. The lymphocytes are mainly small mature lymphocytes but there are scattered reactive lymphocytes. Neutrophils are identified more prominently in some fields but they are not in larger numbers than the lymphocytes. Scattered eosinophils were identified. There are no malignant characteristics in the collection.

**INTERPRETATION OF THE FINDINGS & FURTHER RECOMMENDATIONS**

Liver - Hepatocellular granularity and vacuolization with a mixed cell collection of inflammatory cells including lymphocytes with some neutrophils.

**COMMENTS**

The hepatocytes demonstrate vacuolization and granularity. This suggests a metabolic change in the hepatocytes. This can be secondary to many different conditions including endotoxin absorption from the intestine or I commonly see it with pancreatitis. Copper levels may be increased in this liver. The inflammatory cellularity supports lymphocytic infiltration but there are neutrophils also. This suggests the possibility of an ascending inflammatory process up the biliary tree. Treatment for inflammatory liver disease and evaluation of other organs in the abdominal cavity for a potential source for inflammation including the intestine and pancreas is encouraged after evaluating these smears. A guarded prognosis is warranted since the underlying process is not identified.

**HOSPITAL NAME**

Franklin Lakes AH

**REFERRING VET**

Dr. Onesios

**INVOICE NUMBER**

40704



**DATE**

4/12/23

**INTERPRETED BY**

L.D. McGill, DVM,  
Ph.D, DACVP

**PATIENT**

Maggie Hewitt

**SPECIES**

Canine

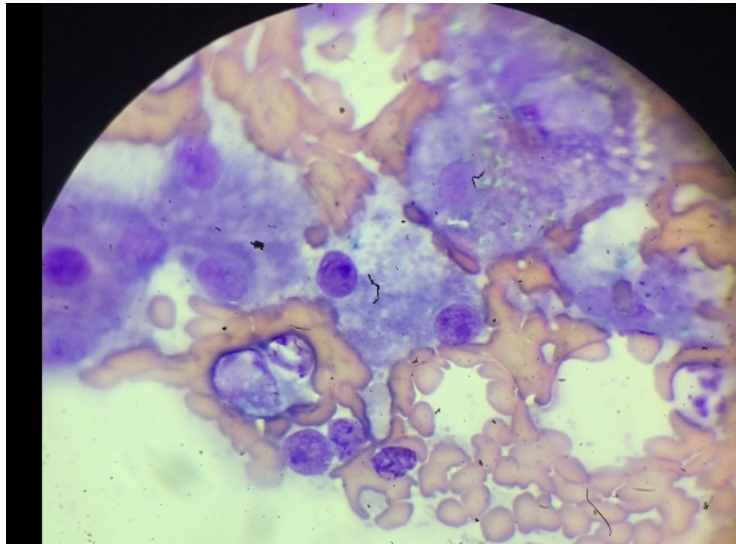


Image shows hepatocytes with lymphocytes and neutrophils associated. The hepatocytes show vacuolization and granularity.

**BREED**

Vizsla

The information and recommendations provided are based on the images presented by the referring veterinarian. No evaluation can be communicated regarding pathology that was not visible in the image/video clips provided.

**SEX**

FS

Thank you for this referral. If the clinical or image interpretation does not parallel your findings or if I can be of any further assistance, please contact me.

**AGE**

13yrs

L.D. McGill, DVM, Ph.D., DACVP  
8288 Top of the World Drive  
Cottonwood Heights, UT 84121  
ldmcgill.vetpath@gmail.com  
cell: 801-865-1220

**WEIGHT**

62#

**HOSPITAL NAME**

Franklin Lakes AH

**REFERRING VET**

Dr. Onesios

**INVOICE NUMBER**

40704