

**DATE PRESENTING CLINICAL SIGNS**

4/11/22

Firm round growth, 16.5mm diameter in skin, dorsal lateral thigh.

**CYTOLOGY SUBMISSION**

FNA of Dermal Dorsal lateral thigh

**INTERPRETED BY**

L.D. McGill, DVM,  
Ph.D, DACVP

**OBSERVATIONS**

Lateral thigh: Submitted are 4 excellent videos of excellent collections of cells from the lesion on the dorsal lateral thigh on Kitty. The cellularity consists of neutrophils and macrophages. The macrophages have a foamy vacuolated cytoplasm. Occasional macrophages contain degenerate debris. There are rare plasma cells and lymphocytes. There are no suggestions of malignant characteristics.

**PATIENT**

Kitty Paoelli

**INTERPRETATION OF THE FINDINGS & FURTHER RECOMMENDATIONS**

Dorsal lateral thigh - Chronic pyogranulomatous inflammation.

**SPECIES COMMENTS**

Canine

The cellularity in this collection is characteristic of an inflammatory process. This inflammatory process could be the result of foreign body penetration or some type of reaction that resulted from trauma. I was unable to identify bacteria in the collection but they could be present. This reaction could be the result of an injection site granuloma. There is no suggestion of sepsis or malignancy in the collection. Treatment for inflammation or excision of the lesion can be considered for therapy. A favorable prognosis is expected assuming that this cellularity in the videos is representative.

**BREED**

Maltese

**SEX**

FS

**AGE**

13Y

**WEIGHT**

10.8lbs

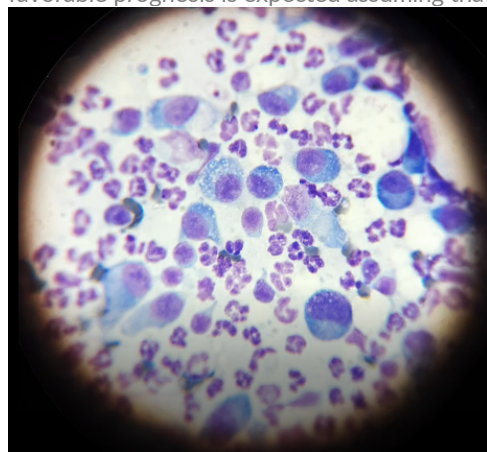


Image shows the neutrophils and macrophages collected from the lesion on Kitty. There is a plasma cell and reactive lymphocyte.

**HOSPITAL NAME**

Rotterdam Veterinary  
Hospital

The information and recommendations provided are based on the images presented by the referring veterinarian. No evaluation can be communicated regarding pathology that was not visible in the image/video clips provided.

Thank you for this referral. If the clinical or image interpretation does not parallel your findings or if I can be of any further assistance, please contact me.

**REFERRING VET**

Dr. Melodee Kopa

**L.D. McGill, DVM, Ph.D., DACVP**  
8288 Top of the World Drive  
Cottonwood Heights, UT 84121  
ldmcgill.vetpath@gmail.com  
cell: 801-865-1220

**INVOICE NUMBER**

40498



**DATE**

4/11/22

**INTERPRETED BY**

L.D. McGill, DVM,  
Ph.D, DACVP

**PATIENT**

Kitty Paoelli

**SPECIES**

Canine

**BREED**

Maltese

**SEX**

FS

**AGE**

13Y

**WEIGHT**

10.8lbs

**HOSPITAL NAME**

Rotterdam Veterinary  
Hospital

**REFERRING VET**

Dr. Melodee Kopa

**INVOICE NUMBER**

40498