



DATE 4/1/2022
PRESENTING CLINICAL SIGNS History of prostatic nodule. Previous FNA and cytology findings from initial sampling done on 2/22/2022 found: Prostate - Necrotic debris with darkly stained material and scattered inflammatory cells.

INTERPRETED BY L.D. McGill, DVM, Ph.D, DACVP
CYTOLOGY SUBMISSION *RE-SAMPLE: U/S-guided FNA of the prostate

PATIENT Kobe Prizzi
OBSERVATIONS Prostate: Submitted are large numbers of images and three videos of excellent collections of cells from the prostate in Kobe. The staining is quite dark. This collection has more distinctive epithelial cells than in the original collection. The dark staining material appears to be degenerate cellular debris. It is prominent throughout many of the images and videos. There are scattered individualized and occasional packets of epithelial cells demonstrating anisocytosis and anisokaryosis. This suggests neoplasia at this location with secondary necrosis.

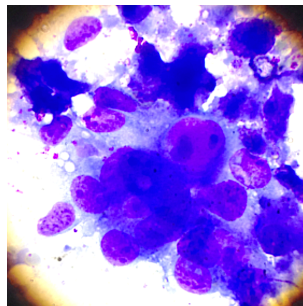
SPECIES Canine
INTERPRETATION OF THE FINDINGS & FURTHER RECOMMENDATIONS Prostate - Suggestive of urothelial carcinoma with extensive necrosis and mild inflammation of the tissue.

BREED Maltipoo
COMMENTS The cellularity in this collection suggests the possibility of a carcinoma since there is moderate anisocytosis and anisokaryosis. Much of the tissue collected is necrotic debris and necrotic cells which are, of course, difficult to identify. Very likely this is a carcinoma and the tumor cells are undergoing necrosis. Traumatic catheterization might assist in confirming the diagnosis. A guarded to unfavorable prognosis is warranted.

SEX Male neutered
 Image below shows one of the groups of cells collected from the prostate in Kobe. Note the prominent anisokaryosis.

AGE 11-year-old

WEIGHT 18 lbs



HOSPITAL NAME Franklin Lakes AH

REFERRING VET Dr. Ward
 The information and recommendations provided are based on the images presented by the referring veterinarian. No evaluation can be communicated regarding pathology that was not visible in the image/video clips provided.

Thank you for this referral. If the clinical or image interpretation does not parallel your findings or if I can be of any further assistance please contact me.

L.D. McGill, DVM, Ph.D., DACVP



DATE 8288 Top of the World Drive
Cottonwood Heights, UT 84121
4/1/2022 ldmcgill.vetpath@gmail.com
cell: 801-865-1220

INTERPRETED BY

L.D. McGill, DVM,
Ph.D, DACVP

PATIENT

Kobe Prizzi

SPECIES

Canine

BREED

Maltipoo

SEX

Male neutered

AGE

11-year-old

WEIGHT

18 lbs

HOSPITAL NAME

Franklin Lakes AH

REFERRING VET

Dr. Ward