



DATE PRESENTING CLINICAL SIGNS

4/1/22

Hx: 4 month duration of vomiting most days (usually food, sometimes liquid, sometimes a small amount of blood seen). Weight has been fluctuating; current weight is down about a pound. Exam: Unremarkable.

INTERPRETED BY CYTOLOGY SUBMISSION

L.D. McGill, DVM,
Ph.D, DACVP

Pyloric area

PATIENT

Binksley Butterfield

OBSERVATIONS

Pyloric area: Submitted are 2 excellent videos of moderate to minimal cellular collections of cells from the pylorus in Binksley. The cellularity is mixed throughout these videos. The major cells are neutrophils. In one of the videos the majority of the cells are mixed necrotic cells with necrotic nuclear debris. There are aggregates of platelets with a background of RBCs. There are a few lymphocytes scattered throughout but they are interspersed with neutrophils. Malignant characteristics are not identified.

SPECIES

Feline

INTERPRETATION OF THE FINDINGS & FURTHER RECOMMENDATIONS

Pyloric area - Chronic suppurative and necrotizing inflammation.

BREED

Russian Blue x

COMMENTS

The cellularity is demonstrating an increased inflammatory process. This easily could be the result of trauma or inflammation associated with the gastric wall at this location. I was unable to identify evidence of malignancy or sepsis. There are certainly changes of chronic inflammation. Treatment for inflammation and bacterial infection is encouraged even without identifying bacterial organisms. A guarded prognosis is warranted. This type of reaction could be the result of a secondary change to neoplasia but I would expect to see more neoplastic cells than I was able to identify in this collection.

SEX

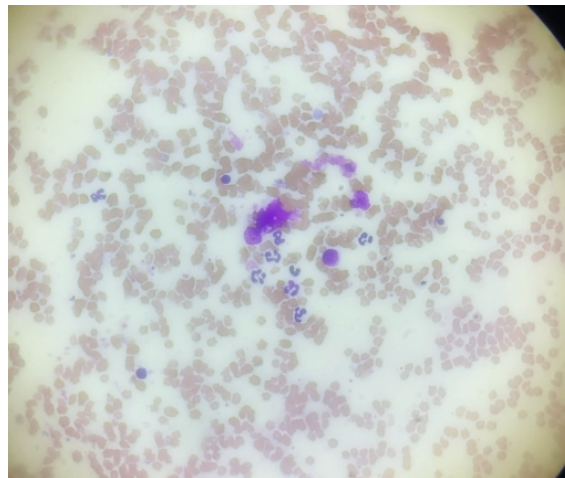
Male Neutered

AGE

11y

WEIGHT

13.18 lbs



HOSPITAL NAME

Santa Clara Animal
Hospital

Image shows neutrophils with some necrotic debris and a mature lymphocyte or 2 collected from Binksley. There are large numbers of RBCs.

REFERRING VET

Dr. Brasted-Maki

The information and recommendations provided are based on the images presented by the referring veterinarian. No evaluation can be communicated regarding pathology that was not visible in the image/video clips provided.

INVOICE NUMBER

703



DATE

4/1/22

Thank you for this referral. If the clinical or image interpretation does not parallel your findings or if I can be of any further assistance please contact me.

INTERPRETED BY

L.D. McGill, DVM,
Ph.D, DACVP

L.D. McGill, DVM, Ph.D., DACVP
8288 Top of the World Drive
Cottonwood Heights, UT 84121
ldmcgill.vetpath@gmail.com
cell: 801-865-1220

PATIENT

Binksley Butterfield

SPECIES

Feline

BREED

Russian Blue x

SEX

Male Neutered

AGE

11y

WEIGHT

13.18 lbs

HOSPITAL NAME

Santa Clara Animal
Hospital

REFERRING VET

Dr. Brasted-Maki

INVOICE NUMBER

703