



DATE PRESENTING CLINICAL SIGNS

3/9/23

Dyspnea and tachypnea, mentioned by owners at Annual Exam. Acting normal per owners. USG thoracocentesis, removed 80 mL almost clear fluid, SG 1.028, TP 4. Cytospin done for cytology. US: moderate to large volume pleural effusion, non-cardiogenic. Consolidated lung lobes diffusely. No free fluid in abdomen.

INTERPRETED BY BW: WNL

L.D. McGill, DVM, Ph.D,
DACVP

CYTOLOGY SUBMISSION

Pleural fluid

PATIENT OBSERVATIONS

Sweetie Pie Charloff

Pleural fluid: Submitted are 8 excellent videos of concentrated cells collected from the pleural fluid in Sweetie Pie. The cellularity is limited but there are moderate numbers of reactive macrophages or mesothelial cells. There are some mature lymphocytes and scattered neutrophils. Malignant characteristics are not identified.

SPECIES INTERPRETATION OF THE FINDINGS & FURTHER RECOMMENDATIONS

Feline

Pleural fluid - Minimal cellularity with mixed cells and scattered lymphocytes suggesting a non-neoplastic or septic pleural fluid. (See comments)

BREED COMMENTS

DLH

The cellularity in this collection is not specific. My original concern is the potential of a chylous fluid with very few cells and particularly very few lymphocytes. This may occur in the cat when the cat is not eating well and has a low-fat diet. There is no suggestion of malignancy or sepsis. The next possibility is some type of cardiovascular problem resulting in pulmonary hypertension and fluid buildup in the thoracic cavity. A guarded to unfavorable prognosis is warranted since the underlying process has not been identified. This collection may be beneficial in the fact that it is not demonstrating neoplasia or sepsis.

SEX

Female Spayed

AGE

7y

WEIGHT

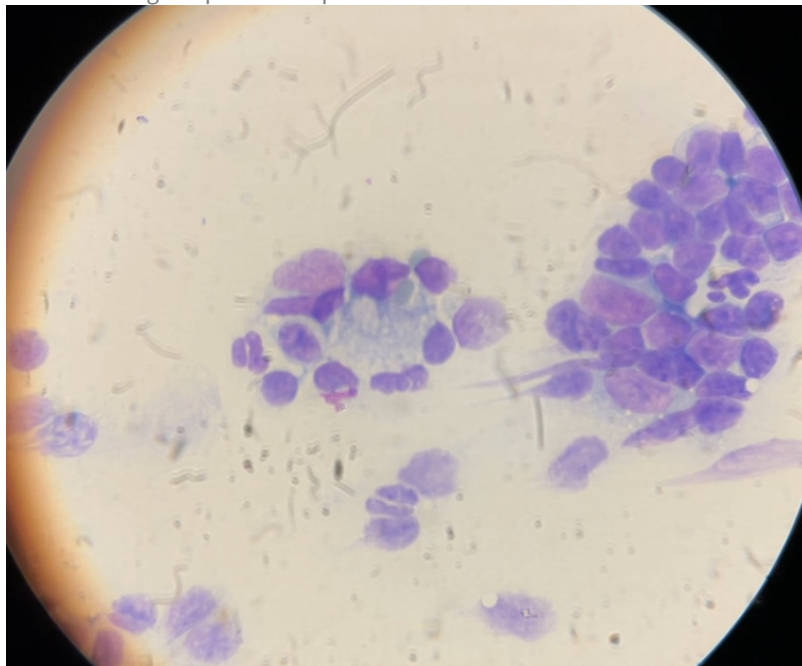
13.5 lbs

HOSPITAL NAME

Scanvetl

REFERRING VET

Dr. Sanders



INVOICE NUMBER

Image shows a representative collection of cells from the fluid in the thorax from Sweetie Pie. There are lymphocytes, neutrophils and reactive macrophages. Malignant characteristics are not identified.



DATE The information and recommendations provided are based on the images presented by the referring veterinarian. No evaluation can be communicated regarding pathology that was not visible in the image/video clips provided.
3/9/23

INTERPRETED BY Thank you for this referral. If the clinical or image interpretation does not parallel your findings or if I can be of any further assistance please contact me.

L.D. McGill, DVM, Ph.D,
DACVP

L.D. McGill, DVM, Ph.D., DACVP
8288 Top of the World Drive
Cottonwood Heights, UT 84121
ldmcgill.vetpath@gmail.com
cell: 801-865-1220

PATIENT

Sweetie Pie Charloff

SPECIES

Feline

BREED

DLH

SEX

Female Spayed

AGE

7y

WEIGHT

13.5 lbs

HOSPITAL NAME

Scanvetl

REFERRING VET

Dr. Sanders

INVOICE NUMBER

910