



**DATE** **PRESENTING CLINICAL SIGNS**  
3/6/23 Frequent vomiting, decreased weight

**INTERPRETED BY** **CYTOLOGY SUBMISSION**  
L.D. McGill, DVM, Ph.D, DACVP FNA of Pancreas

**PATIENT** **OBSERVATIONS**  
Smiles Tyler Pancreas: Submitted are 2 excellent videos of minimal nucleated cellular collections from the pancreas in Smiles. Where cells are present, there are neutrophils interspersed with platelets and blood clot material or mucus. The one image demonstrates a large multi nucleated giant cell which is a macrophage with large numbers of vacuolated structures in the cytoplasm. There is no suggestion of malignancy in any of the cells. Sepsis is not identified.

**SPECIES**  
Feline

**INTERPRETATION OF THE FINDINGS & FURTHER RECOMMENDATIONS**  
Pancreas - Consistent with very mild pyogranulomatous inflammation and probable necrosis.

**BREED**  
DSH

**SEX** **COMMENTS**  
spayed female The minimal cellularity in this collection supports chronic inflammation. It includes neutrophils and the one multi nucleated giant cell which is an inflammatory macrophage giant cell. There is no suggestion of malignancy or sepsis. This supports the likelihood of pancreatitis. Pancreatitis can occur secondarily to other problems including neoplasia but there is no neoplasia suggested in this collection particularly since there are so few cells in the collection. RBCs can be present in many different conditions including as a result of aspiration. At this time, I suspect that pancreatitis is the major process but cannot rule out other pathologic changes with secondary pancreatitis. A guarded prognosis is warranted in Smiles.

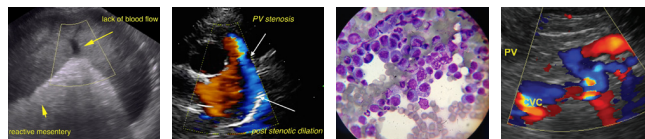
**AGE**  
15yrs

**WEIGHT**  
6.8

**HOSPITAL NAME**  
Central Veterinary Hospital

**REFERRING VET**  
Dr. Anna St. Sir

**INVOICE NUMBER**  
40683



**DATE**

3/6/23

**INTERPRETED BY**

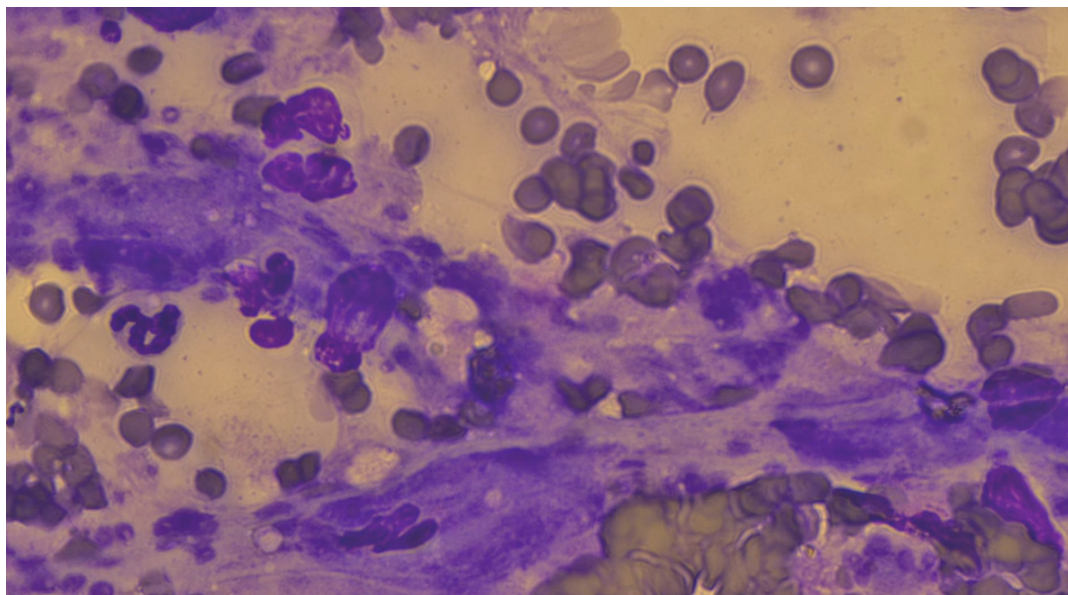
L.D. McGill, DVM,  
Ph.D., DACVP

**PATIENT**

Smiles Tyler

**SPECIES**

Feline



**BREED**

DSH

**SEX**

spayed female

**AGE**

15yrs

**WEIGHT**

6.8

**HOSPITAL NAME**

Central Veterinary  
Hospital

**REFERRING VET**

Dr. Anna St. Sir

**INVOICE NUMBER**

40683

Image shows several neutrophils and clot material, or mucus collected from the pancreas in Smiles. The multinucleated macrophage giant cell was prominent in the other video.

The information and recommendations provided are based on the images presented by the referring veterinarian. No evaluation can be communicated regarding pathology that was not visible in the image/video clips provided.

Thank you for this referral. If the clinical or image interpretation does not parallel your findings or if I can be of any further assistance, please contact me.

L.D. McGill, DVM, Ph.D., DACVP  
8288 Top of the World Drive  
Cottonwood Heights, UT 84121  
ldmcgill.vetpath@gmail.com  
cell: 801-865-1220